

# Treatment of Acne Scars Using the Plasma Skin Regeneration (PSR) System

Michele J. Gonzalez, MD,<sup>1</sup> William H. Sturgill, MD,<sup>1</sup> E. Victor Ross, MD,<sup>2</sup> and Nathan S. Uebelhoer, DO<sup>1,2\*</sup>

<sup>1</sup>Dermatology Department, Naval Medical Center San Diego, San Diego, California

<sup>2</sup>Scripps Clinic, Division of Dermatology, Cosmetic Dermatology Center, San Diego, California

**Background and Objectives:** Acne scarring is a common and difficult to treat condition. The plasma skin regeneration (PSR) system is a novel device that causes delayed ablation of the epidermis and controlled thermal modification to the underlying dermis. PSR has previously been shown to be a safe and effective treatment for facial rhytides and benign skin lesions. In this study, we investigated the safety and efficacy of single-treatment, high-energy, double-pass PSR for the treatment of acne scarring. **Study Design/Materials and Methods:** Ten patients with acne scarring and Fitzpatrick skin types I–III were included in the study. All patients underwent a single PSR treatment with two high-energy passes (3.5–4.0 J). Treatments were performed in an outpatient clinic setting. Nine patients completed 6 months of follow-up. Improvement was determined by patient questionnaires and physician evaluation of digital photographs taken prior to treatment and at 3 and 6 months post-treatment.

**Results:** On average, patients reported 34% improvement in their acne scarring at 3 months and 33% improvement at 6 months. Blinded physician ratings of patient photos demonstrated 19% improvement at 3 months and 34% at 6 months. Re-epithelialization was complete by 4–6 days after treatment, and no serious adverse events were encountered.

**Conclusion:** PSR appears to provide a safe and effective single treatment, minimal downtime alternative for the treatment of acne scarring. Additional studies are warranted to further demonstrate the safety and efficacy of this device. *Lasers Surg. Med.* 40:124–127, 2008.

© 2008 Wiley-Liss, Inc.

**Key words:** plasma skin regeneration; acne scars; non-ablative resurfacing

## INTRODUCTION

Despite the widespread use of isotretinoin and other therapies to aggressively treat acne, scarring from this condition remains a common problem presenting significant therapeutic challenges. Several modalities have been advocated to treat acne scarring, including surgical techniques (punch grafts, punch excisions, subcision), resurfacing techniques (dermabrasion, ablative laser treatment, chemical peels), non-ablative laser treatment, autologous fat transfer, and injection of dermal fillers [1,2]. A combination of different modalities is typically

required to achieve satisfactory results, and each technique carries different risks and side effects.

The plasma skin regeneration system (PSR; Portrait, Rhytec, Inc., Waltham, MA) is a novel device that utilizes radiofrequency (RF) to convert nitrogen gas into a high-energy state of matter called plasma. The plasma is directed onto the skin with the hand-piece of the device, delivering thermal energy in a precise manner. The device causes part or all of the epidermis to become non-viable; however, with the epidermis intact, it acts as a biologic dressing until approximately 2–4 days after treatment when peeling begins. The PSR system has been advocated as an alternative to ablative and fractional resurfacing lasers, with the benefits of lower cost and a better safety profile [3,4]. An in vivo study showed that PSR could consistently achieve thermal injury into the papillary dermis resulting in collagen remodeling without permanent pigmentary or textural irregularities [5]. Following this, multiple sites demonstrated that facial rhytides could be safely and effectively improved with this device [3,6]. Furthermore, PSR has been shown to remove benign skin lesions with similar efficacy and low complication rate as the carbon dioxide (CO<sub>2</sub>) laser [4].

Previous experience with efficacy of the PSR system in treating acne scarring is limited. We hypothesized that the PSR system would be effective in improving acne scars, with minimal down-time and few side effects.

## MATERIALS AND METHODS

The study protocol was approved by our Institutional Review Board and conformed to the guidelines of the 1975 Declaration of Helsinki. Written informed consent was obtained from all patients prior to treatment.

Patients were included in the study if they demonstrated at least a mild degree of atrophic facial acne scarring, were 18 years of age or older, and their acne was either quiescent or under adequate control with medications. Exclusion criteria included pregnancy and lactation, Fitzpatrick skin type IV or higher, history of collagen vascular disease

\*Correspondence to: Dr. Nathan S. Uebelhoer, DO, Dermatology Department, Naval Medical Center San Diego, Suite 300, 34,520 Bob Wilson Drive, San Diego, CA 92134.

Accepted 4 January 2008

Published online in Wiley InterScience

(www.interscience.wiley.com).

DOI 10.1002/lsm.20617

or keloids, history of dermal fillers or dermabrasion, oral retinoids in the previous 12 months, topical retinoids in the previous 2 months, and inability to avoid significant sun exposure during the follow-up period. A total of 10 patients were enrolled and treated.

Prior to treatment, facial photographs were taken. Patients were given cephalexin 500 mg BID and acyclovir 400 mg TID for bacterial and viral prophylaxis, respectively. Pre-operative medications included 75 mg IM meperidine, 50 mg IM hydroxyzine, 1–2 mg PO lorazepam, and topical 4% lidocaine cream applied 30–45 minutes before treatment.

Following a 1 hour training session under the guidance of the principal investigator (NSU), a dermatology resident (MJG) with no prior experience with plasma technology performed one treatment on each subject. A single pass of high-energy plasma (3.5–4.0 J) was delivered to the forehead, mouth and cheeks, followed by a second pass at 4.0 J over only the acne scarred areas. A thick coat of petrolatum was applied to the face after treatment. After 24 hours, patients were instructed to wash the face with a mild cleanser and to apply dilute white vinegar soaks three times a day for 1 week following treatment.

Patient questionnaires were completed and photographs were taken on the day of treatment and at 1 week, 2 weeks, 1 month, 3 months, and 6 months after treatment. Side-lighting was used to accentuate acne scars at the pre-operative, 3-, and 6-month visits (Fig. 1).

## RESULTS

Nine out of 10 patients completed the study and were included in the final analysis. One treated subject that missed the 3-month visit was lost to follow-up.

Immediately after treatment, patients were asked to rate their pain level on a scale from 0 to 8. The average pain reported was 4.6, corresponding to a level of moderate to severe based on the scale used (range 3–7). All patients reported that any discomfort associated with the procedure resolved by the next day.

Desquamation typically began on the third day after treatment, and was complete by the 7-day follow-up visit. Patients commonly reported that the peeling was complete by 1 or 2 days prior to their 1 week visit (5–6 days post-op). Pruritus was a common complaint in the first 2 weeks after treatment and was controlled with oral antihistamines. All facial erythema returned to baseline by the 1 month post-treatment visit. No new textural scarring occurred as a result of the procedure.

Patients were asked to rate the percentage improvement in their acne scars at 3 and 6 months using a scale divided into 10 percentage-point increments. Patients rated the forehead, right cheek, left cheek, and mouth/chin separately, and those numbers were averaged in the analysis. At 3 months, average patient-rated improvement was 34.2% (range 5–70%). At 6 months, average improvement was 33% (range 2.5–90%).

Seven out of 10 patients followed up for facial photography at 3 months, and 9 out of 10 had photography taken at 6 months. Follow-up photographs were compared with

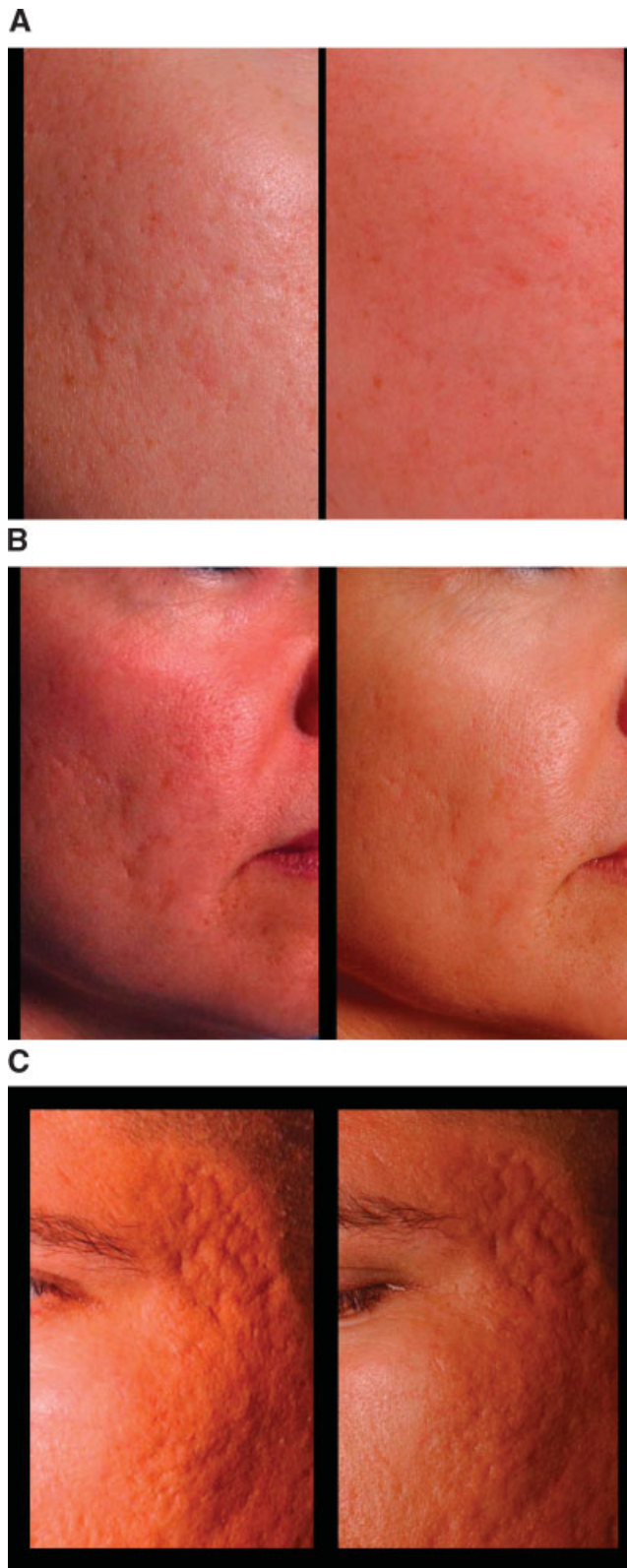


Fig. 1. A–C: Pre-treatment photographs (left) compared to 6 months following a single PSR treatment (right) demonstrating modest improvement in three separate patients with mild scars (A), moderate acne scarring (B) and severe scarring (C).

pre-treatment views and percentage improvement was rated by a blinded assessor (WHS). The following 6-point grading scale was used to rate the before and after photos: 0 for no improvement, 1 for up to 10% improvement, 2 for up to 30% improvement, 3 for up to 50% improvement, 4 for up to 70% improvement, and 5 for up to 90% improvement. The 6 month photos were divided into right-sided and left-sided images and each side was evaluated separately. The 3-month average improvement was rated by the blinded assessor was 19% ( $n = 7$ ; range 0–50%). At 6 months, the blinded average improvement was 34.4% ( $n = 9$ ; range 5–70%). The highest rated side for each patient resulted in an average of 41.1% improvement overall.

Minor adverse events encountered included hyperpigmentation in two patients and a recurrence of herpes labialis in 1 patient. The hyperpigmentation was first seen at the 1-month follow-up in both patients and consisted of a bronze discoloration in the treated areas of the face. One patient had skin type II, was treated with sunscreen, and experienced resolution of the hyperpigmentation by the 6-month follow-up. The other patient was skin type III, was treated with sunscreen and Tri-Luma, and experienced resolution by 3 months. The herpes labialis occurred in a patient with a history of recurrent cold sores, despite complete re-epithelialization and adequate prophylaxis. Symptoms were reported at day 13, the patient was given a second course of oral acyclovir, and the symptoms resolved within 2 days. No patients reported drainage or weeping from the treated sites and all erythema had completely resolved by 1 month following the treatment. No serious adverse events occurred during the follow-up period.

## DISCUSSION

We report a blinded average of up to 41% improvement in facial acne scars 6 months after a single high-fluence treatment with the PSR system. While the magnitude of improvement that we observed in this study is not as dramatic as that seen with multipass ablative CO<sub>2</sub> laser treatment [7], PSR offers several advantages.

First, the PSR is less operator dependent than traditional resurfacing. Most of the desired and adverse effects of CO<sub>2</sub> and Er:YAG ablative resurfacing are due to the depth of thermal injury directly related to the operator's choice of fluence and number of passes. The ability to recognize the level of ablation necessary to achieve dramatic results with ablative lasers without causing permanent scarring or hypopigmentation requires significant experience and skill. Our study demonstrates that, even at high energy, double pass, the PSR requires minimal operator training to achieve predictable and safe effects with modest improvement in acne scars.

In contrast to aggressive ablative techniques, plasma regeneration maintains the integrity of the epidermis leading to less downtime, in terms of persistent erythema and wound care. Most patients are able to return to their typical social activities within 5–7 days after treatment and persistent facial erythema does not appear to be a significant risk. Furthermore, treatment may be performed

in an office setting, avoiding the risks and costs associated with conscious sedation or general anesthesia that may be necessary with other treatments. Finally, since the PSR is an RF-induced nitrogen plasma device there are no special safety measures, such as protective eyewear, required.

Although the pain associated with each treatment during the study required significant use of analgesics and anxiolytics, we have since found that the pain can be well controlled with the adjunctive use of a forced cool air chiller. Since the completion of the study, we routinely use forced cool air (Zimmer MedizinSystems, Irvine, CA) in all treatments with the PSR alleviating the need for systemic analgesics.

One of the biggest issues with CO<sub>2</sub> ablative resurfacing is the delayed-onset hypopigmentation, which can develop 18–24 months post-treatment. To our knowledge, there have been no reports of delayed hypopigmentation occurring with the PSR system. Indeed, even a study investigating CO<sub>2</sub> laser resurfacing to treat acne scars that involved a cohort of 60 patients with skin types I–V and a follow-up time of 18 months showed no occurrences of delayed hypopigmentation [7]. It is possible that acne scarring patients are less likely to experience hypopigmentation after resurfacing, compared with the photoaged population in whom this adverse effect has been reported in the past. One limitation to our study is the fact that patients were only followed for 6 months, which would not be enough follow-up time to capture cases of delayed hypopigmentation, even though we believe this to be an extremely unlikely event.

Our study, similar to others that have evaluated modest textural changes of facial skin over time, is also limited by the use of pre- and post-treatment photography. Although all of our photos were performed by professional photographers in the same studio using the same equipment and lighting techniques, variations in exposure and slight angle differences are noticeable. Despite this, the ratings of improvement noted by the blinded evaluator and those of the patients themselves were fairly consistent. In addition, our study was limited by the number of patients enrolled. To have converted the trends seen in this study to statistical significance would have required a much larger cohort.

## CONCLUSION

In this pilot study, the Portrait PSR appeared to be a safe and effective device for treating facial acne scars. It represents an operator independent single-treatment tool with a relatively tolerable down time. Future studies are needed to explore the potential of repeat treatments to further enhance the textural benefits seen in this study, and to further demonstrate the safety and efficacy of the device.

## REFERENCES

1. Goodman GJ. Postacne scarring: A review of its pathophysiology and treatment. *Dermatol Surg* 2000;26:857–871.
2. Jacob CI, Dover JS, Kaminer MS. Acne scarring: A classification system and review of treatment options. *J Am Acad Dermatol* 2001;45:109–117.

3. Fitzpatrick R, Geronemus R, Kim K, Brown D, Bernstein E. Plasmakinetic skin rejuvenation on perioral rhytides. *Lasers Surg Med Suppl* 2004;16:1–90. Abstract.
4. Potter M, Harrison R, Ramsden A, Penny K, Andrews P, Gault D. A randomised control trial comparing plasma skin resurfacing (PSR) with carbon dioxide laser in the treatment of benign skin lesions. *Lasers Med Sci* 2003;18 (Suppl 1):S1–S67. Abstract.
5. Tremblay JF, Moy RL. Treatment of post-auricular skin using a novel plasma resurfacing system: an in vivo clinical and histologic study. *Lasers Surg Med Suppl* 2004;16:1–90. Abstract.
6. Bogle MA, Arndt KA, Dover JS. Evaluation of plasma skin regeneration technology in low-energy full-facial rejuvenation. *Arch Dermatol* 2007;143:168–174.
7. Walia S, Alster TS. Prolonged clinical and histologic effects from CO<sub>2</sub> laser resurfacing of atrophic acne scars. *Dermatol Surg* 1999;25:926–930.