

Nitrogen Plasma Skin Regeneration and Aesthetic Facial Surgery

Multicenter Evaluation of Concurrent Treatment

J. David Holcomb, MD; Kriston J. Kent, MD; Daniel E. Rousso, MD

Objective: To evaluate the safety and efficacy of aesthetic facial surgery with concurrent nitrogen plasma skin regeneration.

Methods: During a 28-month period, we independently completed 272 concurrent procedures in 95 patients aged 42 to 80 years in whom nitrogen plasma skin regeneration was performed immediately on completion of various aesthetic procedures, including brow-lift, blepharoplasty, lateral canthoplasty, midface-lift, rhytidectomy, cheek augmentation, lip vermillion advancement, filler injections, and augmentation mentoplasty. The treatment variables evaluated included nitrogen plasma pulse energy, pass number, and pulse count, and outcomes monitored included complications and subjective aesthetic improvement.

Results: The various treatment combinations were well tolerated at all anatomical sites. Rhytidectomy flap treat-

ment included escalation of single-pass low-energy to high-energy nitrogen plasma treatment. Although perioperative complications did not otherwise negatively affect results, they included erythema with acneiform eruption (in 2 patients) and presumed herpes simplex virus infection, brief healing delay, and postinflammatory hyperpigmentation (in 1 patient each). In general, the treatment combinations were synergistic.

Conclusions: Combining nitrogen plasma skin regeneration with aesthetic facial surgery enhances outcomes for procedures in the forehead and in the periorbital, midface, and perioral regions. It does not seem to increase the risk of dermatologic or surgical complications for the procedures described herein.

Arch Facial Plast Surg. 2009;11(3):184-193

Author Affiliations: Department of Surgery, University of Florida College of Medicine, Gainesville (Dr Kent); and Department of Surgery and Otolaryngology, University of Alabama at Birmingham (Dr Rousso). Drs Holcomb, Kent, and Rousso are in private practice in Sarasota, Florida; Naples, Florida; and Birmingham, respectively.

THE REALIZATION THAT OPTIMAL facial rejuvenation requires a multifaceted approach with evaluation and treatment of tissue laxity and sagging, bony and soft-tissue volume loss, and skin photoaging and rhytidosis has led to a myriad of procedure combinations designed to maximize results, often in a single operative session. Skin rejuvenation treatments with primarily epidermal tissue effects or little potential to efface rhytids (eg, medium chemical peel¹) have been widely used over areas of tissue undermining.² Deeper more effective skin rejuvenation treatments remote from areas of tissue undermining (eg, perioral deep chemical peel³ or multipass ablative laser peel⁴ with rhytidectomy) have also been routinely used. In contrast, deeper treatments over areas of tissue undermining have become commonplace with a few surgical procedures only, while remaining controversial and less widely practiced with other procedures.

Unresolved questions remain regarding treatment modality, depth of skin rejuvenation necessary for optimal results, and safety when performed over areas of tissue undermining. These issues have been increasingly explored⁵ since the advent of light-based devices that injure tissue in a more predictable manner than chemabrasion or dermabrasion.⁶

Nitrogen plasma skin regeneration is a novel method of skin renewal that uses gaseous diatomic molecular nitrogen as an extracorporeal intermediary and energy reservoir to transduce radiofrequency energy in the device handpiece just before delivery in alternate form (nitrogen plasma) to the skin's surface in a noncontact fashion.¹ The nitrogen plasma energy is rapidly transferred to the skin's surface architecture, with gradient heating of deeper structures via thermal conduction. This creates a dual zone of injury with an outer (superficial) zone of irreversible thermal damage and an inner (deeper) zone of thermal modification.¹

Nitrogen plasma tissue interaction is non-chromophore dependent and is characterized by controlled predictable energy delivery to the skin's architecture, while avoiding certain phenomena (including excessive collateral thermal injury) often associated with ablative (chromophore dependent) laser tissue interaction. In further contrast to ablative lasers, the "old" skin architecture remains intact immediately after nitrogen plasma skin regeneration; there is no open wound. Neopithelialization is rapid and is generally complete within 5 to 7 days following treatment. The old skin architecture serves as a "protective biologic dressing" and undergoes gradual desquamation as the neopidermis appears.¹

The safety and efficacy of aesthetic facial surgery and concurrent nitrogen plasma skin regeneration have not been addressed previously, to our knowledge. This study evaluates the safety of various aesthetic facial surgical procedures with concurrent nitrogen plasma skin regeneration.

METHODS

This study is a retrospective evaluation of our experience with multiple facial aesthetic surgical procedures and concurrent nitrogen plasma skin regeneration. Data were obtained from medical record review at each center, with analysis of compiled data performed by one of us (J.D.H.).

Patient selection for this study included all patients at each study site who underwent various types of aesthetic facial surgery with concurrent nitrogen plasma skin regeneration during the 28-month study period. Nitrogen plasma skin regeneration was performed immediately on completion of various procedures, including brow-lift, upper blepharoplasty, lower blepharoplasty, lower lateral canthoplasty, endoscopic-assisted midface-lift, biplanar (multivector and multiplanar) face-lift, cheek augmentation, upper and lower lip vermilion advancement, superficial musculoaponeurotic system augmentation of upper and lower lips, perioral and midface filler injections, and augmentation mentoplasty. All patients completed appropriate informed consent documents, and all procedures were performed on an outpatient basis in office surgery centers accredited by the Accreditation Association for Ambulatory Health Care.

All patients were carefully followed up postoperatively, with outcomes monitoring for dermatologic and surgical complications and for overall aesthetic improvement. Specific details of the protocol used for concurrent nitrogen plasma skin regeneration follow.

Topical anesthetic (lidocaine [6%] and prilocaine [3.5%] in methylcellulose gel); was applied to the treatment areas and occluded with plastic wrap for a minimum of 20 minutes. The topical anesthetic was gently removed using sterile gauze moistened with an isotonic sodium chloride solution.

Regional nerve blocks (supraorbital, infraorbital, mental, external nasal, and greater auricular) and labial blocks were performed as necessary using lidocaine (0.5%), bupivacaine hydrochloride (Marcaine [0.25%]), and epinephrine (1:200 000). A white cosmetic eyeliner pencil (Beautique, 714021; Sally Beauty Supply, Denton, Texas) was used to draw a grid over the treatment areas to facilitate even and orderly application of nitrogen plasma energy. Supplemental oxygen was turned off and oxygen tubing removed immediately before proceeding with nitrogen plasma skin regeneration.

Nitrogen plasma skin regeneration was performed over the desired areas (typically full face) in the following order: forehead, infraorbital and upper eyelid, lower eyelid, infraorbital and

lateral canthal areas, cheeks, and perioral area. The number of passes, treatment energy, pulse repetition rate, and pulse count were recorded for each region treated. For patients undergoing face-lift, treatment variables for the posterior cheek (undermined) area were recorded independent of those for the anterior (nonundermined) area. If a second pass was deemed necessary, this was completed after the initial pass of the entire region and before moving on to the next region.

Occlusive ointment (Post Procedure Balm; EltaMD Swiss American Products, Inc, Carrollton, Texas) was applied to the treated areas following nitrogen plasma treatment. For patients undergoing brow-lift and face-lift, bismuth-petroleum jelly-impregnated gauze was placed over the treatment areas before placement of a circumferential compression dressing.

Use of an occlusive ointment or gel was continued until completion of desquamation and neopithelialization. Patients undergoing face-lift used compression wear (Universal Facial Band; Design Veronique, Richmond, California) following removal of the initial compression dressing until postoperative day 7. Nonadherent wound dressings were used to prevent direct contact of the compression band with the resurfaced skin of the cheek and perioral areas.

RESULTS

Over a 28-month period (April 5, 2006, through August 21, 2008), 95 patients (93 women and 2 men) were identified who underwent various types of aesthetic facial surgery with concurrent nitrogen plasma skin regeneration. Their mean age was 59.2 years (age range, 42-80 years), and the patients had Fitzpatrick skin types I through IV (8 [8.4%] with type I [always burns, never tans], 54 [56.8%] with type II [burns easily, tans poorly], 31 [32.6%] with type III [tans after initial burn], and 2 [2.1%] with type IV [burn minimally, tans easily]). Two hundred seventy-two concurrent procedures (475 individual treatment areas, including paired and bilateral structures) were performed among 95 patients in whom nitrogen plasma skin regeneration was performed over the surgical treatment area following various aesthetic procedures (**Figure 1**). Among 95 patients, the mean concurrent number of procedures was 2.86 (range, 1-6). Considering the 4 facial regions (forehead, periorbital, cheeks, and perioral), 84 of 95 patients underwent full-face (all 4 regions treated) nitrogen plasma skin regeneration. Five patients underwent treatment of 3 regions, 2 patients had 2 regions treated, and 4 patients had 1 region treated. The mean number of regions treated among all patients was 3.78.

Brow-lift surgery included 3 coronal, 35 endoscopic, and 17 trichophytic procedures. Lower eyelid surgery included 27 transconjunctival blepharoplasties and 8 transcutaneous (skin flap) blepharoplasties in which most undermined skin was resected following limited orbicularis oculi myectomy and repositioning. Where appropriate, nitrogen plasma energy was applied to the lower eyelid skin in a slightly defocused fashion (distal undermined flap only).

All cheek augmentation procedures (10 patients [2 combined malar-submalar and 8 submalar]) involved transoral placement of silicone implants (Implantech Associates Inc, Ventura, California). Eight of 10 patients undergoing cheek augmentation also underwent face-

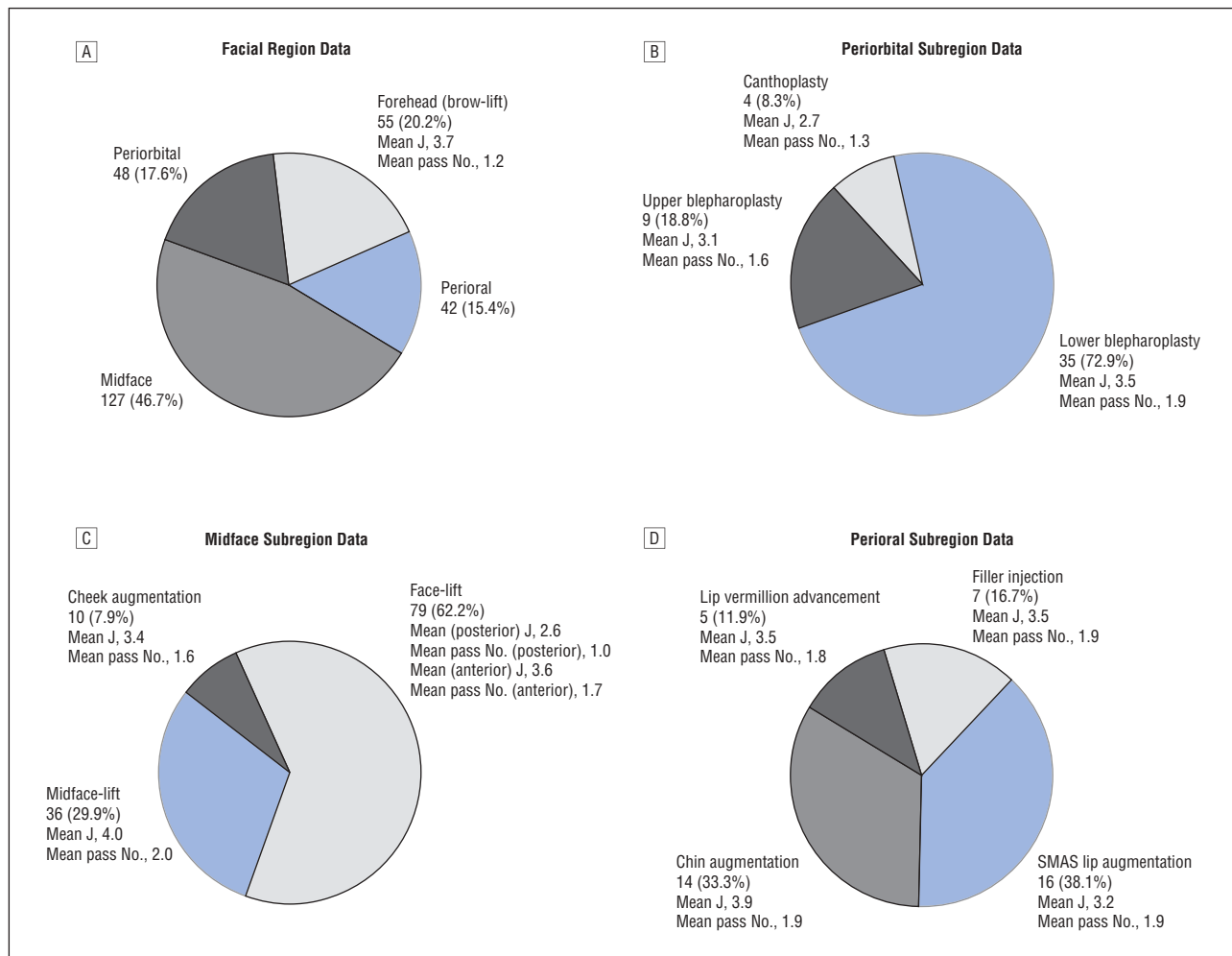


Figure 1. Facial aesthetic surgery and nitrogen plasma skin resurfacing regional facial data. A, Aggregate for all 4 regions. B, Periorbital subregion. C, Midface subregion. D, Perioral subregion. SMAS indicates superficial musculoaponeurotic system.

lift procedures. All patients receiving face-lifts underwent a biplanar (multiplanar and multivector) approach with extensive dissection, mobilization, and imbrication of the superficial musculoaponeurotic system and posterior platysma in the subzygomatic, preauricular, and level II neck areas. Skin undermining of 5 to 7 cm was typically performed in the preauricular areas, with more extensive undermining in the neck and connection of the flaps at the midline in the submentum and anterior part of the neck.

Endoscopic-assisted midface-lift procedures involved transtemporal and transoral approaches with superolateral transposition and anchoring of premaral soft tissues to the deep temporal fascia using a midface soft-tissue device (Endotine; Coapt Systems, Palo Alto, California [1 patient]), 2-0 polydioxanone sutures (Ethicon Inc, Somerville, New Jersey [7 patients]), or ribbon (Endotine Ribbon; Coapt Systems [30 patients]). All chin augmentation procedures involved placement of silicone implants (Implantech Associated Inc) via an external approach. Lip enhancement procedures included 16 augmentations (15 superficial musculoaponeurotic system and 1 VeraFil [Evera Medical, Foster City, California]) and 5 vermilion advancements. Perioral filler injec-

tions involved placement of calcium hydroxyapatite gel (Radiesse; BioForm Medical, Inc, San Mateo, California) into melolabial and melomenal fold areas.

Calcium thrombin-activated platelet concentrate and concentrated platelet-poor plasma were used to facilitate microhemostasis and wound healing over the undermined areas of the forehead, face, and neck in 66 of 79 patients undergoing rhytidectomy and in 45 of 55 patients undergoing brow-lift. Neither passive nor active drains were used with any of the procedures. All patients undergoing rhytidectomy were nonsmokers.

Eleven combinations of concurrent procedures were performed among 95 patients, with the number of concurrent procedures ranging from 4 to 79. The combined mean concurrent number of procedures for each facial region was 68.0 (range, 42-127) (55 forehead, 48 periorbital, 127 midface, and 42 perioral), providing a thorough evaluation of the safety of concurrent treatment within each region (Figure 1).

The mean treatment energy ranged from 2.6 J over the posterior cheek (undermined area) in patients undergoing face-lifts to 4.0 J over the anterior cheek in midface-lift procedures (Figure 1C). Treatment energy ranged from 1.0 J over the posterior cheek (undermined area) in pa-

tients undergoing face-lifts to 4.0 J over the cheeks and perioral region. The number of passes during treatment ranged from 1 (posterior cheek, if undermined in patients undergoing face-lifts) to 2 (multiple areas).

Trends for treatment energy, number of passes, and pulse count generally increased during the evaluation period. For the posterior cheek (undermined area) in patients undergoing face-lift, treatment energy gradually increased before peaking at 3.5 J (**Figure 2**), while the number of passes was limited to 1 for all patients regardless of treatment energy. Regional pulse count data available from one of us (J.D.H.) revealed significant escalation for full-face treatments (best-fit curve), along with (except for one patient described herein) minimal variation ($\leq 12\%$) above the mean for high-energy treatment of the posterior cheeks (undermined area or flap) in patients undergoing rhytidectomy.

Monitoring for dermatologic and surgical complications revealed 5 transient complications among 272 concurrent procedures (1.8%) in 5 patients who required alteration of the postoperative care regimen (**Table 1**). Despite herpes simplex virus prophylaxis with valacyclovir hydrochloride (Valtrex [1 g/d by mouth]), 1 patient who underwent concurrent upper and lower lip vermilion advancement and perioral nitrogen plasma skin regeneration developed atypical herpetic eczema that ultimately required intravenous infusion of antiviral and antibiotic medications. The condition resolved without residual sequelae. A second patient who underwent face-lift and high-energy nitrogen plasma skin regeneration over the cheeks developed an area of delayed healing (defined as requiring >10 days or 50%-100% longer than the time generally required for neoeithelialization) over the left cheek (undermined area). This quickly resolved with administration of a broad-spectrum oral antibiotic (ciprofloxacin hydrochloride [500 mg twice daily] substituted for cephalexin hydrochloride) and with a change in topical wound care treatment (silver sulfadiazine [1% cream] initiated in lieu of Post Procedure Balm). A review of treatment data for this patient identified an elevated regional pulse count for the posterior cheeks (47% higher than the next highest value above the mean for the remaining patients for whom these data were available), which is discussed further in the "Comment" section).

A third patient who had previously undergone full-face carbon dioxide laser skin resurfacing developed mild postinflammatory hyperpigmentation in several areas juxtaposed to preexisting hypopigmentation. Resolution began within 2 months of initiation of treatment with a topical tyrosinase inhibitor (hydroquinone [4%]) and was complete 3 months after treatment. Finally, 2 additional patients developed transient erythematous acneiform eruption in the periorbital area approximately 4 weeks after their procedures, which responded to management with oral tetracycline derivatives (doxycycline calcium or minocycline hydrochloride).

All patients ultimately demonstrated improvement in skin quality, including reduction of dyschromia, smoothing of surface texture, and effacement of rhytids ranging from partial to complete. All of them had readily consented to undergo nitrogen plasma skin regeneration treatment concurrent with their other procedures. Aesthetic

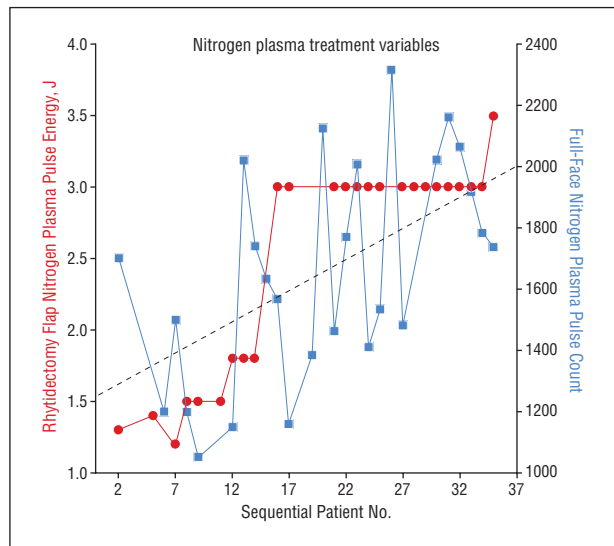


Figure 2. Sequential data from 30 patients treated by one of us (J.D.H.) at one clinic location. Full-face nitrogen plasma skin regeneration treatments were performed in 26 patients, with concurrent biplanar rhytidectomy procedures in 25 of them. Of these 25 patients, 21 underwent full-face nitrogen plasma skin regeneration.

outcomes were perceived by us to reflect substantial synergy, with enhanced results compared with those that might have been achieved with aesthetic facial surgery or nitrogen plasma skin regeneration alone (**Figures 3, 4, 5, 6, and 7**).

COMMENT

High-energy nitrogen plasma treatment initiates a healing response that is best characterized by delayed ablation, rapid neoeithelialization, and extensive dermal remodeling, including neocollagenesis, neolastogenesis, and reversal of elastotic change.¹ Clinical correlates include reduction of photoaging and superficial rhytids, partial-to-complete effacement of medium-depth rhytids, as well as skin tightening and limited improvement of deep rhytids. Many practitioners have enthusiastically embraced nitrogen plasma skin regeneration for its effectiveness, low incidence of untoward effects, and breadth of clinical application (including many treatment options for a range of skin types). Several variables favor the use of nitrogen plasma skin regeneration with aesthetic facial surgery for single-session comprehensive facial rejuvenation, including absence of an open wound, predictable depth of tissue injury, and rapid healing.

Advantages of concurrent skin resurfacing include avoiding additional anesthesia and downtime with secondary procedures,^{7,8} improving outcomes⁶⁻¹⁹ with same-session treatment of moderate to severe skin photoaging and rhytidosis,⁷ and increased practice efficiency and productivity. In addition, patient self-reported outcomes (including perception of youthfulness [number of years younger in appearance]) are significantly improved with concurrent skin rejuvenation vs aging-face surgery alone.⁶

Disadvantages of concurrent skin resurfacing are several. These may include additional anesthesia and

Table 1. Complications of Concurrent Nitrogen Plasma Treatment With Aesthetic Facial Surgery

Concurrent Aesthetic Facial Surgery Procedure	No. of Concurrent Treatment Areas ^a	Complication						
		Delayed Healing ^b	Dyschromia Hypopigmentation	Dyschromia Hyperpigmentation	Wound Dehiscence or Flap Necrosis	Infection	Erythema and Acneiform Eruption	Lower Eyelid Malposition
Brow-lift	55	0	0	0	0	0	0	...
Upper blepharoplasty	18	0	0	0	0	0	0	...
Lower blepharoplasty	70	0	0	0	0	0	2	0
Lower lateral canthoplasty	8	0	0	0	0	0	0	0
Midface-lift	76	0	0	0	...	0	0	...
Biplanar face-lift	158	1	0	0	0	0	0	...
Subperiosteal cheek augmentation	20	0	0	1	...	0	0	...
Lip vermillion advancement	10	0	0	0	0	1	0	...
Superficial musculoaponeurotic system lip augmentation	32	0	0	0	0	0	0	...
Subperiosteal augmentation mentoplasty	14	0	0	0	0	0	0	...
Perioral filler injection	14	0	0	0	...	0	0	...
Total	475	1	0	1	0	1	2	0

^a Reflects paired treatment areas (except for brow-lift and subperiosteal augmentation mentoplasty).

^b Defined as that requiring longer than 10 days (50%-100% longer than the interval generally required for neoepithelialization).

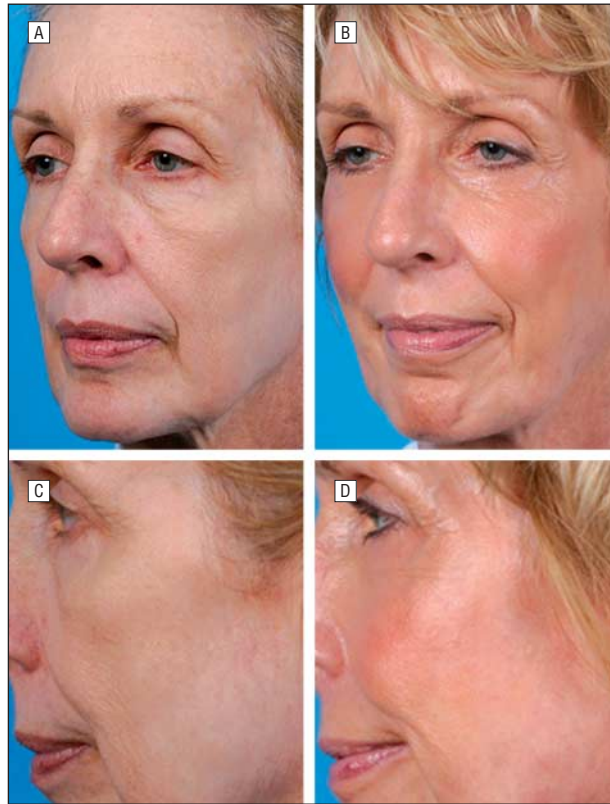

Figure 3. Concurrent submalar augmentation and full-face nitrogen plasma skin regeneration. A and C, Before surgery. B and D, Three months after treatment.

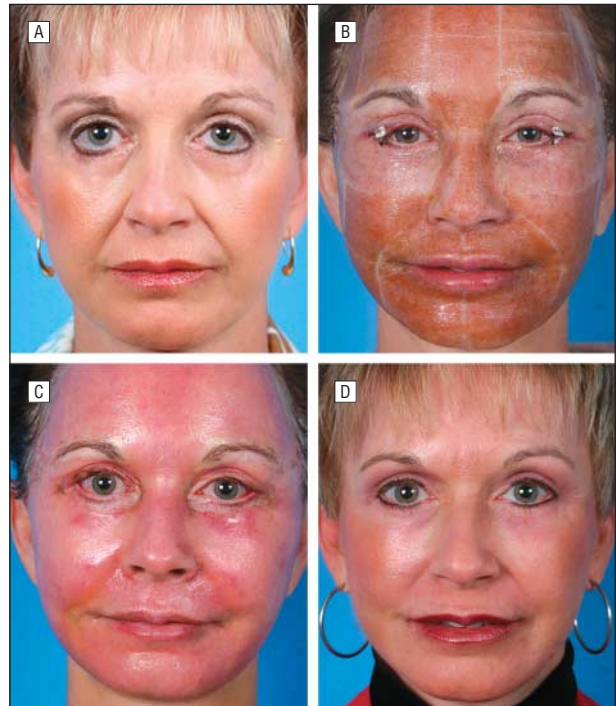

Figure 4. Concurrent lower lateral canthoplasty, biplanar rhytidectomy, perioral filler injections, and full-face nitrogen plasma skin regeneration. A, Before surgery. B, One day after surgery. C, Five days after surgery. D, Four months after surgery.

operative time, greater complexity of postoperative care, increased postoperative edema, worsened initial postoperative appearance, and greater risk of complications.

Presuming similar health status and indications and absence of contraindications, assessment of added risk related to concurrent skin resurfacing requires detailed

knowledge of parameters of the particular skin resurfacing treatment and any additional procedures performed in the treated area(s).¹¹

Contrary to regional skin resurfacing remote from areas of surgical intervention (eg, face-lift with concurrent perioral resurfacing), risk may increase above baseline with facial aesthetic surgery and concurrent skin resurfacing in the immediate treatment area (eg, face-lift with regional laser resurfacing over the undermined area of cheeks). Risk factors include health status, type of skin

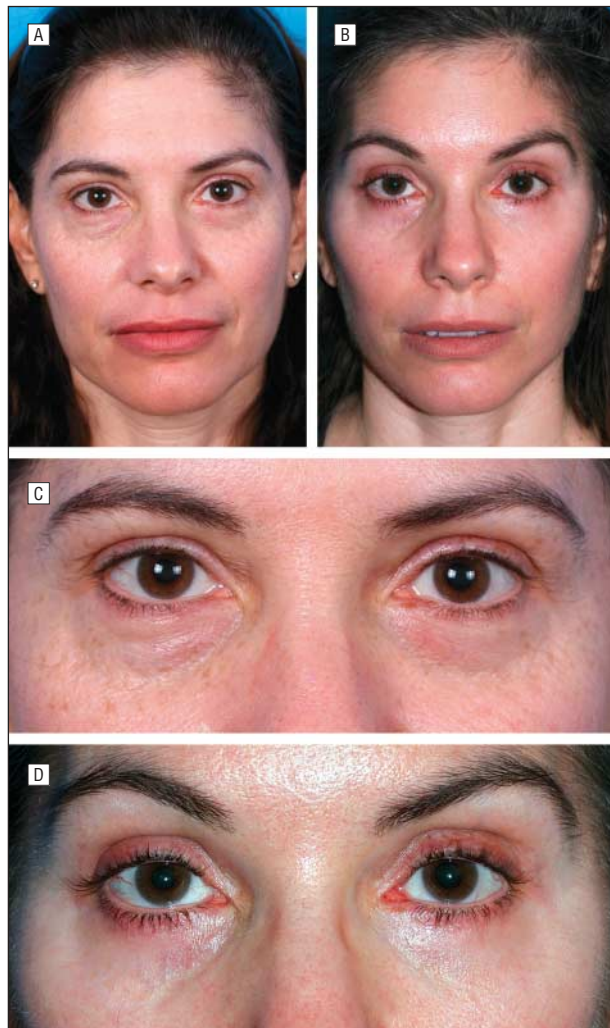

Figure 5. Concurrent coronal brow-lift, transconjunctival lower blepharoplasty, biplanar rhytidectomy, and full-face nitrogen plasma skin regeneration. A and C, Before surgery. B and D, Three months after treatment. C and D, Enlarged to show fine detail of the periorbital region.

resurfacing treatment, numerous modality-specific variables that affect depth of skin resurfacing treatment, facial aesthetic surgery type and location, and certain preoperative (eg, recent use of oral tretinoin and predisposing skin conditions), intraoperative (eg, extent of undermining and skin closure tension), and postoperative (eg, infection and adequacy of skin care) variables.

Numerous studies^{4,21} have evaluated the safety and efficacy of several combinations of procedures (**Table 2**). However, facial aesthetic surgery with concurrent skin resurfacing over the immediate treatment area represents the routine standard of care for a limited number of procedures (eg, transconjunctival lower blepharoplasty with carbon dioxide laser skin resurfacing of the lower eyelid and infraorbital region).^{4,7-10,12,16,18,20}

Despite extension of the modality to other combinations of treatments, the application and execution of concurrent laser skin resurfacing and aesthetic facial surgery are limited by Fitzpatrick skin type, potential for prolonged erythema, patient acceptance, and other factors. While continuing to perform concurrent carbon dioxide laser skin resurfacing and aesthetic facial surgery,

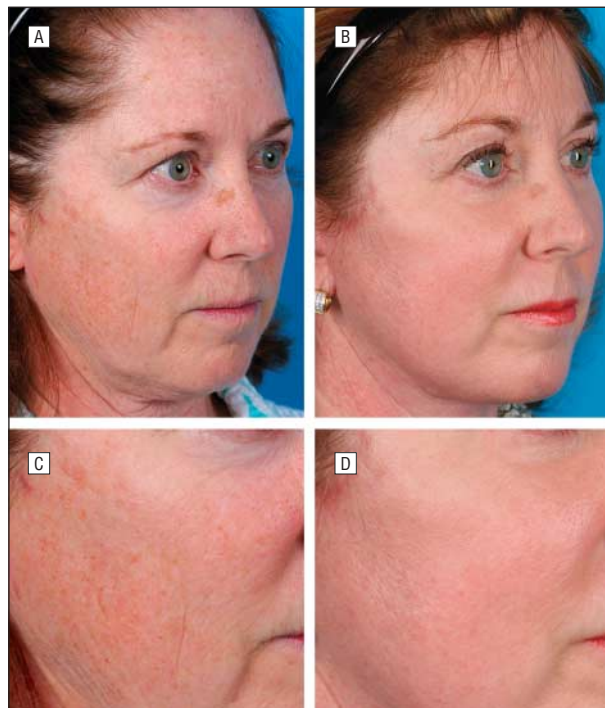

Figure 6. Concurrent trichophytic brow-lift, transcutaneous lower blepharoplasty, biplanar rhytidectomy, superficial musculoaponeurotic system augmentation of lips, and full-face nitrogen plasma skin regeneration. A and C, Before surgery. B and D, Three months after treatment. C and D, Enlarged to show fine detail of lower eyelid and cheek skin.

many surgeons have modified several variables (eg, number of passes, treatment energy, and pulse duration) in an attempt to reduce initial healing time and duration and severity of postresurfacing erythema.

Citing safety concerns, unpredictable thermal effects, and imprecise estimation of resurfacing depth, some surgeons have moved away from carbon dioxide laser resurfacing in favor of erbium:YAG laser systems that more efficiently and precisely effect skin ablation.⁸ With lengthening of the pulse width, erbium:YAG lasers are able to achieve effects comparable to those of carbon dioxide laser, with significant tissue contraction and effacement of deep rhytids. Even so, proponents of aesthetic facial surgery and erbium:YAG laser skin resurfacing have advocated less aggressive (limited ablation without long pulse) treatment of undermined tissue (eg, rhytidectomy flap).⁸

Nitrogen plasma skin regeneration has emerged as an attractive alternative to ablative laser skin resurfacing. It offers more rapid healing, greater utility across the spectrum of Fitzpatrick skin types, posttreatment skin quality that is more reminiscent of native skin qualitatively and histologically,¹ and fewer complications but comparable efficacy (eg, single-pass medium- to high-fluence carbon dioxide laser skin resurfacing).²²

Findings from this study support the safety and efficacy of facial aesthetic surgery with concurrent nitrogen plasma skin regeneration. Nitrogen plasma skin regeneration was found to be safe with brow-lift surgery and with various aesthetic procedures of the periorbital, midface, and perioral regions. Synergy was observed in all facial regions with all procedures performed, including those with significant tissue undermining (eg, rhyti-

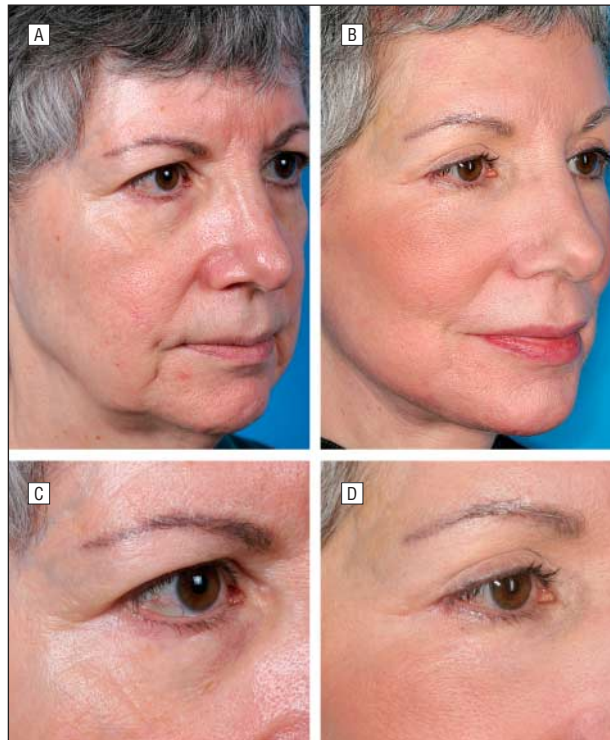

Figure 7. Rapid healing and minimal erythema 1 month after concurrent trichophytic brow-lift, upper blepharoplasty, lower lateral canthoplasty, biplanar rhytidectomy, superficial musculoaponeurotic system augmentation of lips, and full-face nitrogen plasma skin regeneration. A and C, Before surgery. B and D, One month after treatment. C and D, Enlarged to show fine detail of the periorbital region.

dectomy) and subcutaneous or subperiosteal augmentation (eg, filler injections or facial implants). No permanent complications were observed. The observed transient complications are not unique to nitrogen plasma skin regeneration and have been previously reported with other skin resurfacing procedures.²³⁻²⁶

Infection (including perioral herpes simplex activation) complicating skin rejuvenation treatments has been reported for dermabrasion, deep chemical peeling, and ablative laser resurfacing. Perioral herpes simplex activation has been reported as a complication of various lip enhancement procedures. A 2.4% incidence (1 case per 42 concurrent procedures) of perioral herpes simplex activation is less than previous findings for isolated lip enhancement or skin resurfacing procedures in this region.^{23,24}

Delayed reepithelialization has been observed to complicate ablative skin resurfacing procedures.^{25,26} Although regional complications related to concurrent laser resurfacing and cervicofacial rhytidectomy have been infrequently reported, several variables must be considered when weighing the safety and efficacy of concurrent resurfacing of the posterior cheek during rhytidectomy.¹¹

In the present study, a single case of slightly delayed neoeithelialization occurred in 1 of 272 concurrent treatment procedures (0.4%). However, because many procedures involved bilateral or paired treatment areas (upper blepharoplasty, lower blepharoplasty, lower lateral canthoplasty, midface-lift, cheek augmentation, rhytidectomy, lip augmentation, lip vermilion advancement, and perioral filler injections), the incidence of de-

layed neoeithelialization among individual treatment areas is even lower (1 of 475 treatment areas [0.2%]). The affected area involved the left cheek in a patient undergoing rhytidectomy without cheek augmentation and was restricted to a small nondistal portion of the undermined skin. Although the area ultimately healed without residual textural irregularity or discoloration, the possible contributing circumstances deserve additional consideration and are discussed in further detail herein. Considering only concurrent treatment of the cheek in rhytidectomy procedures, the incidence of delayed healing of the flap is slightly higher (0.6%) among all patients undergoing rhytidectomy and is higher still (0.9%) among patients who underwent concurrent high-energy single-pass treatment of the flaps (54 of 79 patients receiving rhytidectomy).

Independent of concurrent surgical procedures, variables that may affect healing after nitrogen plasma skin regeneration include preprocedure, intraoperative, and postoperative factors. Unique to nitrogen plasma treatment, skin hydration is likely the most significant preoperative variable. Nitrogen plasma treatment of inadequately hydrated skin may lead to less predictable tissue response related to greater depth of effect. Important variables during nitrogen plasma treatment include treatment technique, treatment energy, and number of passes.

In a patient with delayed healing, the nitrogen plasma pulse count for treatment of the posterior cheeks (underrmined area or flap) exceeded the next highest value above the mean by 47%. Therefore, excessive pulse overlap may have been a significant contributing factor for delayed healing in this patient. However, the regional treatment zone surface area was not evaluated, and the higher pulse count may be partially explained by the greater area of the treatment zone in this patient.

Although the treatment depth and the zone of irreversible tissue damage are generally increased or deepened by additional passes with ablative lasers, these variables do not change significantly with additional high-energy nitrogen plasma passes.^{1,27} The lack of significant extension of the injury depth with a second high-energy nitrogen plasma pass is likely attributable to an insulating effect related to changes in the basal epidermis (development of pericellular edema or vacuolation) following the initial high-energy pass.¹ A second high-energy pass (if performed) is not intended to increase bulk heating or to result in immediate pulse stacking. Indeed, the rationale for a second high-energy nitrogen plasma pass is improved coverage and greater uniformity of treatment.

High-energy single- or double-pass nitrogen plasma treatment elicits thermal effects at a level within the dermis ($\leq 500 \mu\text{m}^1$) that a nonfractionated ablative laser (eg, carbon dioxide and erbium:YAG) can reach only after multiple passes. At similar depths of middermal injury, clinical improvements result from different characteristics of healing following primarily irreversible tissue damage (coagulative effect of ablative lasers) vs primarily reversible tissue damage (nitrogen plasma). **Figure 8** shows preservation of the epidermis and thermal denaturation of collagen (reversible tissue damage or zone of thermal modification) into the middermis following high-energy nitrogen plasma treatment.

Table 2. Concurrent Skin Rejuvenation With Aesthetic Facial Surgery

Concurrent Aesthetic Facial Surgery Procedure	Skin Rejuvenation Method		Nitrogen Plasma Skin Rejuvenation (Present Study)
	Erbium-YAG Laser	Carbon Dioxide Laser	
Brow-lift	Weinstein et al, ⁸ 2001; EN	Ramirez and Pozner, ¹⁵ 1996, EN; Fulton, ¹⁶ 1998, UN; Roberts and Ellis, ¹⁰ 1998, EN; Weinstein, ¹⁷ 1998, EN; Graf et al, ⁵ 1999, EN; Achauer et al, ⁹ 2000, EN; Badin et al, ¹⁹ 2001, EN; Koch and Perkins, ¹¹ 2002, UN; Alster et al, ⁷ 2004, EN	CO, EN, TP
Upper blepharoplasty	Alster et al, ⁷ 2004	Fulton, ¹⁶ 1998; Roberts and Ellis, ¹⁰ 1998; Graf et al, ⁵ 1999; Achauer et al, ⁹ 2000; Seckel, ¹² 2000; Alster et al, ⁷ 2004	Yes
Lower blepharoplasty	Alster et al, ⁷ 2004; TC	Fulton, ¹⁶ 1998, TC; Roberts and Ellis, ¹⁰ 1998, TC; Graf et al, ⁵ 1999, TC; Achauer et al, ⁹ 2000, UN; Seckel et al, ¹² 2000, TC; Carter et al, ¹⁸ 2001, TC; Rizk and Matarasso, ²⁰ 2003, TC; Alster et al, ⁷ 2004, TC; Trelles et al, ⁴ 2005, TC	EX, TC
Lower lateral canthoplasty or canthopexy	...	Roberts and Ellis, ¹⁰ 1998, CP; Graf et al, ⁵ 1999, CE; Seckel et al, ¹² 2000, CE	CP
Face-lift	Weinstein et al, ⁸ 2001; BP	Fulton, ¹⁶ 1998, SM; Roberts and Ellis, ¹⁰ 1998, SM; Bisaccia et al, ¹⁴ 1998, UN; Graf et al, ⁵ 1999, SM; Achauer et al, ⁹ 2000, SM; Jackson et al, ¹³ 2000, SM; Roberts et al, ⁶ 2000, SP; Koch and Perkins, ¹¹ 2002, BP; Alster et al, ⁷ 2004, SL; Trelles et al, ⁴ 2005, SM	BP
Midface-lift	Badin et al, ¹⁹ 2001; Weinstein et al, ⁸ 2001	Ramirez and Pozner, ¹⁵ 1996; Badin et al, ¹⁹ 2001	Yes
Malar-submalar augmentation	...	Ramirez and Pozner, ¹⁵ 1996, M	M, SM
Augmentation mentoplasty	...	Koch and Perkins, ¹¹ 2002	Yes
Lip vermilion advancement vs subnasal lip lift	...	Achauer et al, ⁹ 2000, LL; Fulton et al, ²¹ 2000, LL	VA
Augmentation (superficial musculoaponeurotic system vs fat vs injectable filler) of lips or face	Trelles et al, ⁴ 2005; IF, IL	Graf et al, ⁵ 1999, FL; Fulton et al, ²¹ 2000, FL; Trelles et al, ⁴ 2005, IF, IL	IF, IL, SML

Abbreviations: BP, biplanar; CE, lower lateral canthopexy; CO, coronal brow-lift; CP, lower lateral canthoplasty; EN, endoscopic brow-lift; EX, transcutaneous lower blepharoplasty; FL, fat transfer to lips; IF, injectable filler to face; IL, injectable filler to lips; LL, subnasal lip lift; M, malar augmentation; SM, submalar augmentation; SML, superficial musculoaponeurotic system augmentation lips; SP, subperiosteal; TC, transconjunctival lower blepharoplasty; TP, trichophytic brow-lift; UN, unknown; VA, lip vermilion advancement.

Few wrinkles are typically present over the posterior cheek,⁸ especially after tissue rearrangement associated with cervicofacial rhytidectomy; therefore, less aggressive resurfacing is needed in this area in the context of a concurrent or staged procedure. Accordingly, concurrent nitrogen plasma treatment of the face-lift flap was initiated at the lowest energy setting (1.0 J). However, treatment of the face-lift flap with low energy (≤ 2.0 J) in the first 25 patients undergoing rhytidectomy yielded inferior results compared with treatment with high energy (≥ 3.0 J) in the subsequent 54 patients undergoing rhytidectomy. After escalating through the low-energy treatment range with disappointing results (eg, incomplete elimination of dyschromia over the face-lift flap and obvious transition from areas treated with low vs high energy), we elected to then treat the face-lift flap using a single high-energy pass (treatment variables sufficient to replace the epidermis and to cause extensive remodeling of the upper dermis), with excellent clinical results. A paradoxical lengthening of healing time of several days until completion of desquamation was observed over the face-lift flap when treated with low vs high energy; faster healing for concurrent treatment of the face-lift flap was another desirable outcome with the use of high energy. Despite theoretic safety, a




Figure 8. Polarized photomicroscopy of human skin with picosirius red F3BA staining 2 days after high-energy (3.5 J) nitrogen plasma treatment. The green arrow shows irreversibly damaged epidermis, while the red double arrow delineates a wide band of thermally denatured collagen (no longer birefringent) extending into the middermis (original magnification $\times 100$). Photomicrograph courtesy of Rhytec, Ltd, Berkshire, England.

second high-energy pass was not performed over the flap, as high-energy single-pass treatment seemed adequate.

Important posttreatment factors include infection, adequacy of skin care, and other unknown variables. Neoepithelialization is typically complete within 5 to 7 days after high-energy nitrogen plasma skin regeneration. For this study and as a general benchmark for future comparisons, delayed healing after nitrogen plasma skin regeneration was defined as that requiring longer than 10 days (50%-100% longer than the interval generally required for neoepithelialization). In some cases, delayed healing may be more aptly described as a temporary breakdown of previously healed tissue, perhaps related to infection, desiccation, inadvertent wounding (unintended rubbing or scratching), or another unexplained phenomenon.

Surgical variables that may affect outcomes related to concurrent resurfacing (eg, nitrogen plasma) of the face-lift flap in patients undergoing rhytidectomy include extent of skin flap undermining, skin flap closure tension, and skin flap thickness, with each potentially affecting skin flap blood supply and ultimately skin flap viability.²⁸ Depending on such variables, the surgeon should be prepared to modulate previously anticipated treatment variables (eg, increase treatment nozzle offset from the skin surface and/or decrease treatment energy) or, if significant concern regarding face-lift flap viability, to abort nitrogen plasma treatment over the posterior cheek region.

Postinflammatory hyperpigmentation has been reported after other skin resurfacing treatments and is more likely to occur with darker skin types.²³ In our experience, pretreatment and posttreatment with a topical tyrosinase inhibitor may prevent or minimize postinflammatory hyperpigmentation among patients with darker skin types who undergo nitrogen plasma skin regeneration treatment.

Lower eyelid malposition (eg, mild retraction or rounding), a known sequela of periorbital ablative laser skin resurfacing,²⁹ has not been reported or observed by us following high-energy single- or double-pass nitrogen plasma treatment of the lower eyelid and infraorbital area. Nevertheless, linear skin contraction exceeding 10% has been observed in controlled clinical experiments,³⁰ and we have observed substantial tissue tightening following high-energy nitrogen plasma skin regeneration. Although treatment energy of 4.0 J was routinely used in conjunction with transconjunctival blepharoplasty, treatment energy did not exceed 3.0 J in conjunction with transcutaneous blepharoplasty. Release of lower eyelid retractors with transconjunctival blepharoplasty may have contributed to the apparent safety of maximum high-energy treatment of the lower eyelid and infraorbital region. Therefore, caution is advised with high-energy nitrogen plasma treatment of the lower eyelid and infraorbital region, especially with any preexisting lower eyelid abnormality.

In some patients, lower eyelid rounding or laxity is present. In these patients, we advocate consideration of lateral canthoplasty with temporary tarsorrhaphy when performing nitrogen plasma skin regeneration of the infraorbital area.

Using the described protocol, combining nitrogen plasma skin regeneration with aesthetic facial surgery does not seem to substantially increase the risk of dermato-

logic or surgical complications for the procedures described herein. Excessive pulse overlap (or immediate pulse stacking) may contribute to delayed tissue healing and should be avoided. The combination of nitrogen plasma skin regeneration and aesthetic facial surgery is readily accepted and well tolerated by patients and results in synergistic improvement of outcomes for procedures in the forehead, periorbital, midface, and perioral areas.

Concurrent nitrogen plasma skin regeneration adds another dimension to facial rejuvenation such that substantial overall improvement may be obtained and some of the pitfalls of more extreme surgical or skin resurfacing measures may be avoided. Moreover, the benefits of nitrogen plasma skin regeneration continue to accrue over time, with skin quality, tone, and texture typically peaking 6 months or longer after treatment, well beyond the time when maximum results are realized for surgical facial rejuvenation. For some patients, this continuing improvement may enable a change of focus in the postoperative period and a corresponding positive shift in the dynamics of the physician-patient relationship. Investigations evaluating the efficacy of a new nitrogen plasma energy paradigm³¹ for treatment of deep rhytids are under way, raising the possibility of even greater synergy with future concurrent therapies.

Accepted for Publication: December 18, 2008.

Correspondence: J. David Holcomb, MD, Holcomb Facial Plastic Surgery, 1 S School Ave, Ste 800, Sarasota, FL 34237 (drholcomb@srqfips.com).

Author Contributions: Dr Holcomb had full access to all of the data in the study and takes responsibility for the integrity of the data and the accuracy of the data analysis. *Study concept and design:* Holcomb. *Acquisition of data:* Holcomb, Kent, and Rouso. *Analysis and interpretation of data:* Holcomb. *Drafting of the manuscript:* Holcomb. *Critical revision of the manuscript for important intellectual content:* Holcomb, Kent, and Rouso. *Statistical analysis:* Holcomb. *Administrative, technical, and material support:* Holcomb.

Financial Disclosure: Dr Holcomb has received speakers bureau honoraria and unrelated study funding from Rhytec, Inc.

Previous Presentation: This study was presented at the annual fall meeting of the American Academy of Facial Plastic and Reconstructive Surgery; September 18, 2008; Chicago, Illinois.

Additional Contributions: Matt T. Scott, BA, helped with formatting patient photographs for Figures 1 through 7. Rhytec, Ltd provided the photomicrograph for Figure 8.

REFERENCES

1. Kilmer S, Semchyshyn N, Shah G, Fitzpatrick R. A pilot study on the use of a plasma skin regeneration device (Portrait® PSR³) in full facial rejuvenation procedures. *Lasers Med Sci.* 2007;22(2):101-109.
2. Dingman DL, Hartog J, Siemionow M. Simultaneous deep-plane face lift and trichloroacetic acid peel. *Plast Reconstr Surg.* 1994;93(1):86-93, discussion 94-95.
3. Becker FF. Circumoral chemical peel combined with cervicofacial rhytidectomy. *Arch Otolaryngol.* 1983;109(3):172-174.
4. Trelles MA, Brychta P, Stanek J, et al. Laser techniques associated with facial aesthetic and reparative surgery. *Facial Plast Surg.* 2005;21(2):83-98.

5. Graf RM, Bernardes A, Auerswald A, Noronha L. Full-face laser resurfacing and rhytidectomy. *Aesthetic Plast Surg.* 1999;23(2):101-106.
6. Roberts TL III, Pozner JN, Ritter E. The RSVP facelift: a highly vascular flap permitting safe, simultaneous, comprehensive facial rejuvenation in one operative setting. *Aesthetic Plast Surg.* 2000;24(5):313-322.
7. Alster TS, Doshi SN, Hopping SB. Combination surgical lifting with ablative laser skin resurfacing of facial skin: a retrospective analysis. *Dermatol Surg.* 2004;30(9):1191-1195.
8. Weinstein C, Pozner J, Scheffan M. Combined erbium:YAG laser resurfacing and face lifting. *Plast Reconstr Surg.* 2001;107(2):586-592, discussion 593-594.
9. Achauer BM, Adair SR, VanderKam VM. Combined rhytidectomy and full-face laser resurfacing. *Plast Reconstr Surg.* 2000;106(7):1608-1611, discussion 1612-1613.
10. Roberts TL III, Ellis LB. In pursuit of optimal rejuvenation of the forehead: endoscopic brow lift with simultaneous carbon dioxide laser resurfacing. *Plast Reconstr Surg.* 1998;101(4):1075-1084.
11. Koch BB, Perkins SW. Simultaneous rhytidectomy and full-face carbon dioxide laser resurfacing: a case series and meta-analysis. *Arch Facial Plast Surg.* 2002;4(4):227-233.
12. Seckel BR, Kovanda C, Cetrulo CL Jr, Passmore AK, Meneses PG, White T. Laser blepharoplasty with transconjunctival orbicularis muscle/septum tightening and periocular skin resurfacing: a safe and advantageous technique. *Plast Reconstr Surg.* 2000;106(5):1127-1141, discussion 1142-1145.
13. Jackson IT, Yavuzer R, Beal B. Simultaneous facelift and carbon dioxide laser resurfacing: a safe technique? *Aesthetic Plast Surg.* 2000;24(1):1-10.
14. Bisaccia E, Sequeira M, Magidson J, Scarborough D. Surgical intervention for the aging face: combination of mini-face-lifting and superficial carbon dioxide laser resurfacing. *Dermatol Surg.* 1998;24(8):821-826.
15. Ramirez OM, Pozner JN. Subperiosteal minimally invasive laser endoscopic rhytidectomy: the SMILE facelift. *Aesthetic Plast Surg.* 1996;20(6):463-470.
16. Fulton JE. Simultaneous face lifting and skin resurfacing. *Plast Reconstr Surg.* 1998;102(7):2480-2489.
17. Weinstein C. Carbon dioxide laser resurfacing combined with endoscopic forehead lift, laser blepharoplasty and transblepharoplasty corrugators muscle resection. *Dermatol Surg.* 1998;24(1):63-67.
18. Carter SR, Seiff SR, Choo PH, Vallabhanath P. Lower eyelid CO₂ laser rejuvenation: a randomized, prospective clinical study. *Ophthalmology.* 2001;108(3):437-441.
19. Badin AZ, Casagrande C, Roberts T III, et al. Minimally invasive facial rejuvenation endolaser mid-face lift. *Aesthetic Plast Surg.* 2001;25(6):447-453.
20. Rizk SS, Matarasso A. Lower eyelid blepharoplasty: analysis of indications and the treatment of 100 patients. *Plast Reconstr Surg.* 2003;111(3):1299-1306, discussion 1307-1308.
21. Fulton JE Jr, Rahimi DA, Helton P, Watson T, Dahlberg K. Lip rejuvenation. *Dermatol Surg.* 2000;26(5):470-475.
22. Rothhaus KO, Fitzpatrick R. A retrospective analysis of the safety profiles of a new plasma skin regeneration device compared to CO₂ lasers [abstract No. 89]. In: Proceedings from the American Academy of Cosmetic Surgery; January 17-20, 2008; Orlando, FL.
23. Nanni CA, Alster TS. Complications of carbon dioxide laser resurfacing: an evaluation of 400 patients. *Dermatol Surg.* 1998;24(3):315-320.
24. Perkins SW, Sklarew EC. Prevention of facial herpetic infections after chemical peel and dermabrasion: new treatment strategies in the prophylaxis of patients undergoing procedures of the perioral area. *Plast Reconstr Surg.* 1996;98(3):427-435.
25. Collawn SS. Re-epithelialization of the skin following CO₂ laser resurfacing. *J Cosmet Laser Ther.* 2001;3(3):123-127.
26. Svedman C, Agner T, Esmann J. Delayed healing after CO₂ laser resurfacing. *J Cosmet Laser Ther.* 2003;5(3-4):183-184.
27. Fitzpatrick R, Bernstein E, Iyer S, Brown D, Andrews P, Penny K. A histopathologic evaluation of the plasma skin regeneration system (PSR) versus a standard carbon dioxide resurfacing laser in an animal model. *Lasers Surg Med.* 2008;40(2):93-99.
28. Carniol PJ. The importance of blood supply in combination rhytidectomy and full-face carbon dioxide laser resurfacing [commentary]. *Arch Facial Plast Surg.* 2002;4(4):234.
29. Miedziak AI, Gottsch JD, Iloff NT. Exposure keratopathy after cosmetic CO₂ laser skin resurfacing. *Cornea.* 2000;19(6):846-848.
30. Tremblay J, Moy R. Treatment of post-auricular skin using a novel plasma resurfacing system: an in-vivo clinical and histologic study [abstract]. In: Proceedings from the American Society for Laser Medicine and Surgery; March 31-April 4, 2004; Dallas, TX.
31. Fitzpatrick R, Holcomb JD, Sibbons P. Unique two-step neocollagenesis response using plasma energy for wrinkle reduction and skin rejuvenation [abstract No. 90]. In: Proceedings from the American Society for Laser Medicine and Surgery; April 2-6, 2008; Kissimmee, FL.

Announcement

Visit www.archfacial.com. As an individual subscriber to *Archives of Facial Plastic Surgery*, you have full-text online access to the journal from 1999 forward. In addition, you can download PowerPoint slides of figures and tables, use My Folder to organize articles of interest, and access abstracts from *JAMA* and the other *Archives* journals.