Received: 2 February 2022 | Revised: 21 June 2022 | Accepted: 15 July 2022

DOI: 10.1111/jocd.15280

JCD Journal of Cosmetic Dermatology WILEY

ORIGINAL ARTICLE

Effectiveness of combined use of targeted pressure energy, radiofrequency, and high-intensity focused electromagnetic fields to improve skin quality and appearance of fat and muscle tissue in different body parts

Diane Irvine Duncan MD, FACS[1] | Mariano Busso MD[2]

[1]Plastic Surgical Associates, Fort Collins, Colorado, USA

[2]Dr. Busso Cosmetic Dermatology, Miami, Florida, USA

Correspondence
Diane Irvine Duncan, Plastic Surgical Associates of Fort Collins PC, 1701 E Prospect Rd, Fort Collins, CO 80525, USA.
Email: momsurg@aol.com

Abstract

Background: Inevitable signs of aging are especially noticeable in middle to elder age when stretch marks, loose skin, cellulite, and body-contour changes naturally appear.

Aims: To verify efficacy of high-intensity focused electromagnetic field (HIFEM), radiofrequency (RF), and Targeted Pressure Energy (TPE) combination treatment to address unfavorable changes in skin, fat, and muscle tissue.

Methods: The device simultaneously emitting monopolar RF and TPE energies was consecutively combined with simultaneous HIFEM+RF procedure in 32 subjects (21–64 years, 17.4–33.5 kg/m^2) for treatment of thighs ($N = 15$; back, inner, or front), buttocks/saddlebags ($N = 7$), abdomen ($N = 8$), and upper arms ($N = 2$). All patients underwent four weekly, combined treatments of 30-min HIFEM+RF procedure followed by 15–30 min RF+TPE, depending on treatment area. Circumferential measurements, digital photographs, subject satisfaction, and comfort questionnaires were assessed up to 3-months post-treatment.

Results: Majority of participants found treatments comfortable, no adverse events occurred. Subjects showed substantial improvement in all treated areas from 1-month follow-up. Combination of HIFEM+RF, monopolar RF, and TPE resulted in significant circumference decrease. Generally, more pronounced results were seen at 3 months when subjects showed −5.2 cm on abdomen, −3.0 cm on thighs, and −5.5 cm on saddlebags, respectively. Ninety-four percent of subjects were satisfied with treatment results, most noticed improvement in cellulite, skin laxity, and muscle definition.

Conclusions: Results showed high patient satisfaction and efficacy in improving body contour and skin quality. Combining simultaneous HIFEM+RF procedure with simultaneous monopolar RF+TPE treatments considerably enhanced body contour and skin tissue. The procedure proved versatile and may effectively treat multiple body parts.

KEYWORDS
abdominal remodeling, body contour, buttock, HIFEM, radiofrequency

1 | INTRODUCTION

The field of aesthetic medicine has experienced a new shift with the recent introduction of advanced non-invasive body shaping procedures. As a result, spending and investment in the aesthetics market continue to rise, driving growth and innovation. Skin treatments, tightening, and liposuction remain in the top five of procedures done in the USA in the first half of 2021.[1] Recently, a novel approach of combining simultaneous high-intensity focused electromagnetic procedure (HIFEM) and synchronized radiofrequency (RF) with a simultaneous monopolar RF and targeted pressure energy (TPE) has come to the forefront.[2] This technique is among the top trends that may safely provide favorable outcomes with high satisfaction and no downtime, rivaling traditional and modern methods.[3–9]

The combined application of HIFEM+RF is effective for simultaneous muscle toning and fat reduction.[10–13] HIFEM generates an electromagnetic field that activates neuromuscular tissue by induced electric current, leading to supramaximal muscle contractions, which create a significant energy demand causing muscles to utilize the energy stored in the adipocytes in free fatty acid form.[4,14,15] This leads to a reduction in size and, under the extreme muscle load, decreased number of adipocytes. In addition, the synchronized RF generates adjustable heat that predominantly accumulates in the fat tissue, leading to selective heating of adipocytes within 42–45°C, inducing adipocyte apoptosis. The heat also penetrates the underlying muscle tissue, delivering a synergistic effect with HIFEM, significantly increasing the activation of myosatellite cells, responsible for muscle fiber growth and differentiation.[16,17]

Target pressure energy (TPE) and monopolar RF are frequently used for treating skin laxity and cellulite noninvasively, albeit as separate modalities.[18,19] The mechanical energy provided by TPE accelerates fibroblast proliferation,[20] creating a suitable environment for neocollagenesis and neoelastogenesis by reducing oxidative stress in tissue. Simultaneous emission of monopolar RF (thermal energy) and TPE (mechanical energy) activates the collagen degradation function of metalloproteinase (MMP) in the extracellular matrix.[21] The mechanical stress results in fibrils dissociation, increasing their conformational freedom and reducing thermal stability. This, therefore, decreases the temperature required for collagen denaturation. Heating collagen to the critical temperature of 42°C stimulates the production of HSP47 protein,[22] which is involved in the formation of new collagen and ensures the tertiary structure of collagen, which is essential for correct collagen functionality. Higher cell membrane permeability is achieved through thermal and mechanical energy tissue stimulation, leading to accelerated cell metabolism.[23] Combination of both energies stimulates blood circulation and angiogenesis, leading to lipase activation[24] that causes reduction of fat chambers through adipocyte breakdown.

This study investigates the effectiveness of the consecutive application of HIFEM+RF and TPE+RF procedures on different body areas in subjects seeking non-invasive treatment of skin, fat, and muscle tissue for body contouring, improvement of skin health, and enhanced aesthetic appearance.

2 | MATERIALS AND METHODS

2.1 | Study population and design

Thirty-two (32; 1 male and 31 females) subjects participated in this non-randomized, single-arm, open-label, prospective study conducted at two study sites. Selection criteria included healthy men and women with a body mass index (BMI) below 35 kg/m^2. Exclusion criteria were pregnancy, postpartum period, breastfeeding, injury in the treatment area, or any other medical conditions that contraindicate the application of electromagnetic fields and RF such as cardiovascular disease, malignant tumor, metal, or electronic implants. After receiving detailed instructions about the study and signing informed consent, qualifying subjects were enrolled in the study. The study protocol conformed to the ethical guidelines of the 1975 Declaration of Helsinki, informed consent forms were obtained from each subject at the time of recruitment, and subjects were not financially compensated for either participation or completion of the study.

At enrollment, the group had an average age of 45.7 ± 11.5 years (21–64 years) and a BMI averaging 23.8 ± 3.0 kg/m^2 (17.4–33.5 kg/m^2). The treatment areas included abdomen (N = 8), thighs (N = 15; back, inner or front), saddlebags/buttocks (N = 7), and upper arms (N = 2). Each subject received four 30-min treatments with the Emsculpt Neo (BTL Industries Inc., Boston, MA) device simultaneously delivering HIFEM+RF energies through a single applicator. Two specific applicator types were used, that is, large applicators for broad treatment areas and small applicators for curved treatment areas. Once positioned, the applicator remained fixed through the duration of therapy due to the flexible tape. The magnetic field intensity (0%–100%) was adjusted according to the subject's tolerability, and the intensity of radiofrequency energy was set to 100% from the start. Patients were regularly asked about the therapy comfort throughout the treatment administration, and the energy settings were adjusted accordingly. Consecutive treatment with Emtone device (BTL Industries Inc, Boston, MA) delivering simultaneous RF+TPE followed. The intensity of radiofrequency energy was initially set at a lower level (40%–50% of maximum output) and further adjusted up to 85% according to the patient feedback. The TPE pressure was set at 4 bar throughout the therapy. The applicator tip was kept in a constant circular motion over the treatment area, where conductive cream was applied to maintain good contact with the skin throughout the treatment duration. Each subject received four weekly treatments that lasted up to 20 min, depending on the treated area.

2.2 | Data collection and evaluation

Weight, BMI, digital photographs, and circumference of the treated area (thighs, saddlebags, abdomen, and upper arms) were recorded at baseline, 1-month, and 3-month follow-up visits. The circumference

was measured using a stretch-resistant tape and average pre- and post-treatment circumference were compared. Moreover, the objective was to determine patient's comfort and subject satisfaction with the aesthetic end-result of consecutive HIFEM+RF and RF+TPE therapy by using a 5-point Likert scale questionnaire administered after the last treatment and at each follow-up visit. Throughout the study, potential adverse events and side effects were closely monitored. Where applicable, the data were statistically analyzed using the Student's paired T-test (Real Statistics Resource Pack for Microsoft Excel).

3 | RESULTS

Each treatment area had a pronounced decrease in circumference at all follow-up stages. In addition, there was a significant circumferential reduction seen in the thighs, saddlebags, and abdomen. Thigh circumference was reduced by 1.5 cm ($p<0.01$) and 3.0 cm ($p<0.01$) at one-month and three-month follow-up visits, respectively. Saddlebag circumference reduced significantly by 5.3 cm ($p<0.05$) and 5.5 cm ($p<0.05$) at one-month and three-month follow-ups, respectively. Abdominal circumference reduced by 6.1 cm ($p<0.05$) and 5.2 cm ($p<0.05$) at one- and three-month post-treatment. Lastly, the upper-arm circumference reduced by 0.2 cm and 2.5 cm at one- and three-month follow-up visits. At the 1-month and 3-month follow-ups, 93.8% ($N = 32$) and 77.4% ($N = 31$) subjects had decreased circumference in the treatment area. Detailed results are shown in Table 1.

Subject satisfaction questionnaire analysis showed a very high patient satisfaction of 93.8% (30 out of 32) with the treatment outcomes. At least 92.9% ($N = 28$) and 93.3% ($N = 30$) of the treated subjects reported an improvement in cellulite and skin laxity, respectively. The average Likert scale score for cellulite and skin laxity improvement was 4.0 (agree). Additionally, the majority of patients (88%), found the treatment procedure comfortable.

Digital photographs showed considerable improvement in body image and skin quality (see Figures 1–4). Apart from visible muscle definition and fat-reducing effect, the simultaneous treatments also resulted in skin tightening and cellulite reduction. Furthermore, there were no severe adverse events or side effects related to the treatments. Lastly, BMI and weight did not significantly fluctuate in between any of the time points.

TABLE 1 Average circumference at baseline, 1-month, and 3-month follow-up visits

	Circumference (centimeters)		
Treatment area	**Baseline**	**1 month**	**3 months**
Abdomen ($n = 8$)	92.4 ± 10.8	86.3 ± 5.2	87.1 ± 8.2
Thighs ($n = 15$)	63.1 ± 7.4	61.6 ± 6.8	60.1 ± 6.0
Saddlebags ($n = 7$)	117.9 ± 10.4	112.6 ± 8.5	112.4 ± 7.1
Upper arms ($n = 2$)	27.7 ± 2.9	27.5 ± 3.7	25.2 ± 2.1

4 | DISCUSSION

Women, especially in developed countries, tend to grapple with challenges such as their weight and appearance.[25] Limitations related to poor diet choices, lack of exercise with an increased sedentary lifestyle and the natural aging process, make it difficult to achieve ideal body image goals conventionally. Skin quality also deteriorates as the body ages, contributing to poor self-esteem.

The procedure combining Emsculpt Neo and Emtone devices offers a promising opportunity to treat multiple types of tissue (skin, fat, and muscle) in one sitting. Emsculpt Neo (HIFEM+RF) treats the underlying muscle and subcutaneous fat and Emtone (TPE+RF) treatment is for the skin and fat pockets in the treatment area. Moreover, the therapy is highly versatile, producing distinguishable results in thighs, saddlebags, abdomen, and upper arms, which are all problematic areas when it comes to fat distribution and deposition.[26,27] This easily administered therapy offers a convenient alternative to subjects, requiring no physical exertion or demanding routine whatsoever.

In our study, the HIFEM+RF procedure has led to a marked fat reduction on various body parts. The most reduction was seen in the abdomen, which is especially affected by centripetal fat deposition. The subsequent decrease in circumference is determined by the thickness of the fat layer beneath the skin in the treatment area, as described in previous study,[10] some body parts are prone to fat accumulation.[27] To put this into perspective, the average fat reduction in the abdomen and saddlebags was higher (5.2 cm and 5.5 cm) than in the thighs (3.0 cm) at 3 months post-treatment in the given subject sample. Furthermore, the TPE+RF noticeably countered the skin laxity and cellulite through induced changes in connective tissue. Skin quality degenerates as connective tissue fibers in the skin (collagen and elastin) stretch and do not recover, thus diminishing in quality. The effect of radiofrequency heating on the skin is the production of new structural components of the connective tissue fiber.[28–30] Moreover, the appearance may be improved by the lymphatic drainage effect due to both RF[31] and TPE.[32,33] Thus, the healthiness and appearance of the skin in the treated area improved, as seen in Figures 1–4.

Circumference results in this current study are superior to previous research where standalone RF+TPE procedure was used for abdominal skin laxity improvement. In our study, we found 6.1 cm and 5.2 cm significant decrease in abdominal circumference at 1-month and 3-month follow-up, respectively, compared with 1.4 cm in a previous research by Fritz et al.[28]

The significance of achieved results was documented by remarkably positive patient satisfaction feedback. Ninety-four (94%) percent of patients were satisfied with the treatment results while most of them also noticed an improvement in cellulite (92.9%) and skin laxity (93.3%) after 3 months. At least 93% of subjects had reduced circumference one month after the last treatment, and this reduction in circumference was sustained in 77% of subjects three months after the final treatment. The therapy was safe with mild but tolerable heating sensation mainly attributed to the TPE+RF procedure. To

FIGURE 1 Female abdomen before (left) and 1 month after (right) combined treatment with RF, HIFEM, and TPE. The subject achieved considerable fat reduction accompanied by core muscle enhancement. The umbilical area appears tighter suggesting possible shortening of diastasis (abdominal muscle separation)

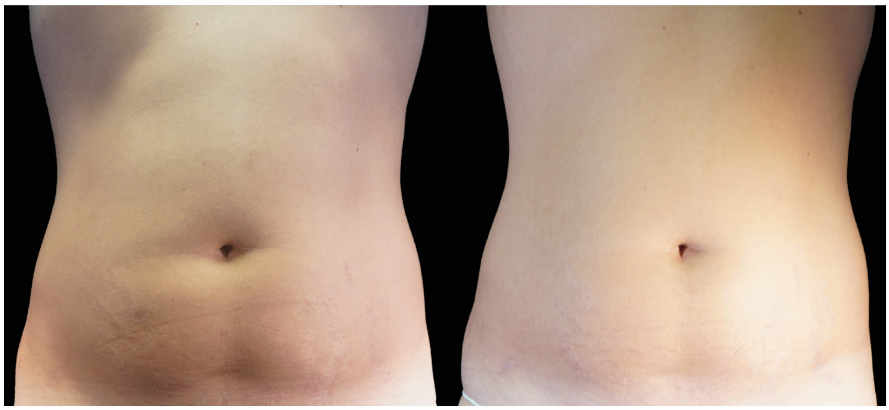

FIGURE 2 Male abdomen before (left) and 3 months after (right) combined treatment with RF, HIFEM, and TPE. After the treatments, there is a better abdominal muscle definition. Skin texture appears smoother, the fine lines have reduced, and skin looks more tight

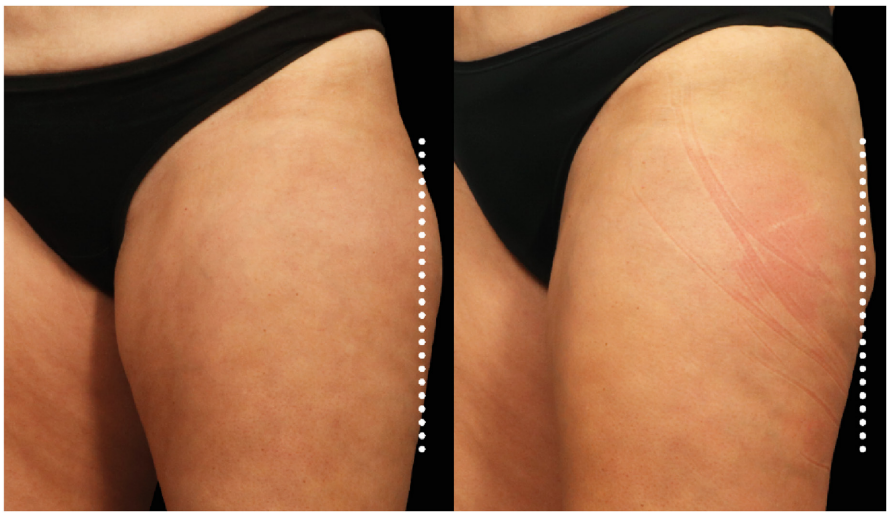

FIGURE 3 Female outer thigh before (left) and 1 month after (right) combined treatment with RF, HIFEM, and TPE. The fat pocket is not bulging out/protruding after the treatments. The outer thigh appears/is more toned and shapely

FIGURE 4 Female lateral thigh and buttock area before (left) and 1 month after (right) combined treatment with RF, HIFEM, and TPE. The contour of the buttock is rounder and lifted. The skin condition improved remarkably, as the cellulite bumps and dimples evened out

the best of our knowledge, this was the first study that investigated the consecutive use of HIFEM+RF and TPE+RF therapies in multiple body parts.

Despite the study group showing consistent results regardless of the treatment site, the study's major limitation is variable patient count depending on the treatment area. Especially in the upper arm subgroup, only two subjects were treated, and further investigation will be needed to fully clarify the treatment effect in this particular area. Further studies with a larger study subject number per treatment region would further clarify which regions respond best. The TPE+RF combination mainly targets skin tissue and fat protrusions to address skin laxity and cellulite,[28] whereas the HIFEM+RF modality primarily affects muscle tissue and fat.[10,11,13–15] There is limited research that has been conducted to study the effects of combined HIFEM, RF, and TPE modalities,[34] this however should not negate the results of this herein study or the efficacy of the proposed treatment. Measurement of skin surface variability using either a topographic mapping technique or linear waveform analysis might better document the degree of improvement in the skin smoothing effect of TPE plus RF. Nonetheless, in general, the results elucidated the usability of this combined therapy, revealing its future potential in non-invasive aesthetic body shaping.

5 | CONCLUSION

Our findings indicate that combining the HIFEM + Synchronized RF and Monopolar RF+TPE treatments considerably enhances visual appearance through changes in fat, muscle, and skin tissue. Results showed high patient satisfaction and efficacy for improving body image and skin quality. The procedure proved to be versatile, and thus, may be recommended for the effective and safe treatment of multiple body parts to influence the unwanted effects of aging.

ACKNOWLEDGMENTS

None.

CONFLICT OF INTEREST

Diane I. Duncan is a clinical investigator for BTL Industries Inc.

DATA AVAILABILITY STATEMENT

The data that support the findings of this study are available from the corresponding author upon reasonable request.

ETHICS STATEMENT

The authors confirm that the ethical policies of the journal, as noted on the journal's author guidelines page, have been adhered to. Prior to inception, the protocol was reviewed and approved by an independent research ethics committee. All patients signed a study participation consent and informed treatment consent, as well as consent to share pre-treatment and post-treatment photographs. The authors and staff have completed and been certified in the CITI GCP (Good Clinical Practice) program.

ORCID

Diane Irvine Duncan https://orcid.org/0000-0002-3904-900X

REFERENCES

1. *The Aesthetic Society Releases Annual Statistics Revealing Significant Increases*. The Aesthetic Society. Published April 11, 2022. Accessed April 25, 2022. https://www.surgery.org/media/news-releases/the-aesthetic-society-releases-annual-statistics-revealing-significant-increases
2. Duncan D, Chilukuri S, Kent D, Hoffmann K, Tingsong L. *Non-Invasive Alternatives for Liposuction*. IntechOpen; 2022. doi:10.5772/intechopen.101396
3. Katz BE. An overview of HIFEM technology in body contouring. *Dermatol Rev*. 2020;1(3):91-96. doi:10.1002/der2.24
4. Goldberg DJ, Enright KM, Goldfarb R, Katz B, Gold M. The role and clinical benefits of high-intensity focused electromagnetic devices for non-invasive lipolysis and beyond: a narrative review and position paper. *J Cosmet Dermatol*. 2021;20(7):2096-2101. doi:10.1111/jocd.14203
5. Mazzoni D, Lin MJ, Dubin DP, Khorasani H. Review of non-invasive body contouring devices for fat reduction, skin tightening and muscle definition. *Australas J Dermatol*. 2019;60(4):278-283. doi:10.1111/ajd.13090
6. Giesse S. A German prospective study of the safety and efficacy of a non-invasive, high-intensity, electromagnetic abdomen and buttock contouring device. *J Clin Aesthet Dermatol*. 2021;14(1):30-33.
7. Verner I. A novel nonfocused pulsed ultrasound technology for noninvasive circumference reduction. *Dermatol Ther*. 2021;34(5):e15101. doi:10.1111/dth.15101
8. Kwan KR, Kolansky Z, Abittan BJ, Farberg AS, Goldenberg G. Skin tightening. *Cutis*. 2020;106(3):134-137;139;E1. doi:10.12788/cutis.0073
9. Sadick N. Treatment for cellulite. *Int J Womens Dermatol*. 2018;5(1):68-72. doi:10.1016/j.ijwd.2018.09.002
10. Jacob C, Kent D, Ibrahim O. Efficacy and safety of simultaneous application of HIFEM and synchronized radiofrequency for abdominal fat reduction and muscle toning: a multicenter magnetic resonance imaging evaluation study. *Dermatol Surg*. 2021;47(7):969-973. doi:10.1097/DSS.0000000000003086
11. Halaas Y, Duncan D, Bernardy J, Ondrackova P, Dinev I. Activation of skeletal muscle satellite cells by a device simultaneously applying high-intensity focused electromagnetic technology and novel RF technology: fluorescent microscopy facilitated detection of NCAM/CD56. *Aesthet Surg J*. 2021;41(7):NP939-NP947. doi:10.1093/asj/sjab002
12. Duncan D. A novel technology combining RF and magnetic fields: technical elaboration on novel RF electrode design. *AJBSR*. 2020;11(2):147-149. doi:10.34297/AJBSR.2020.11.001608
13. Samuels JB, Katz B, Weiss RA. Radiofrequency heating and high-intensity focused electromagnetic treatment delivered simultaneously: the first sham-controlled randomized trial. *Plast Reconstr Surg*. 2022 May;149(5):893e-900e. doi:10.1097/PRS.0000000000009030
14. Weiss RA, Bernardy J, Tichy F. Simultaneous application of high-intensity focused electromagnetic and synchronized radiofrequency for fat disruption: histological and electron microscopy porcine model study *Dermatol Surg*. Published online June 2, 2021. doi:10.1097/DSS.0000000000003091
15. Goldberg DJ. Deletion of adipocytes induced by a novel device simultaneously delivering synchronized radiofrequency and hifem: human histological study. *J Cosmet Dermatol*. 2021;20(4):1104-1109. doi:10.1111/jocd.13970
16. Kinney BM, Kent DE. MRI and CT assessment of abdominal tissue composition in patients after high-intensity focused

electromagnetic therapy treatments: one-year follow-up. *Aesthet Surg J*. 2020;40(12):NP686-NP693. doi:10.1093/asj/sjaa052
17. Duncan D, Dinev I. Noninvasive induction of muscle fiber hypertrophy and hyperplasia: effects of high-intensity focused electromagnetic field evaluated in an in-vivo porcine model: a pilot study. *Aesthet Surg J*. 2020;40(5):568-574. doi:10.1093/asj/sjz244
18. Arora G, Patil A, Hooshanginezhad Z, et al. Cellulite: presentation and management. *J Cosmet Dermatol*. 2022;21(4):1393-1401. doi:10.1111/jocd.14815
19. de Lima Morais TM, Meyer PF, de Vasconcellos LS, et al. Effects of the extracorporeal shock wave therapy on the skin: an experimental study. *Lasers Med Sci*. 2019;34(2):389-396. doi:10.1007/s10103-018-2612-8
20. Vetrano M, d'Alessandro F, Torrisi MR, Ferretti A, Vulpiani MC, Visco V. Extracorporeal shock wave therapy promotes cell proliferation and collagen synthesis of primary cultured human tenocytes. *Knee Surg Sports Traumatol Arthrosc*. 2011;19(12):2159-2168. doi:10.1007/s00167-011-1534-9
21. Freitas-Rodríguez S, Folgueras AR, López-Otín C. The role of matrix metalloproteinases in aging: tissue remodeling and beyond. *Biochim Biophys Acta (BBA) – Mol Cell Res*. 2017;1864(11):2015-2025. doi:10.1016/j.bbamcr.2017.05.007
22. Ito S, Nagata K. Roles of the endoplasmic reticulum–resident, collagen-specific molecular chaperone Hsp47 in vertebrate cells and human disease. *J Biol Chem*. 2019;294(6):2133-2141. doi:10.1074/jbc.TM118.002812
23. Christ C, Brenke R, Sattler G, Siems W, Novak P, Daser A. Improvement in skin elasticity in the treatment of cellulite and connective tissue weakness by means of extracorporeal pulse activation therapy. *Aesthet Surg J*. 2008;28(5):538-544. doi:10.1016/j.asj.2008.07.011
24. Levy AS, Grant RT, Rothaus KO. Radiofrequency physics for minimally invasive aesthetic surgery. *Clin Plast Surg*. 2016;43(3):551-556. doi:10.1016/j.cps.2016.03.013
25. Evert AB, Franz MJ. Why weight loss maintenance is difficult. *Diabetes Spectr*. 2017;30(3):153-156. doi:10.2337/ds017-0025
26. Bosomworth NJ. Normal-weight central obesity. *Can Fam Physician*. 2019;65(6):399-408.
27. Goossens GH. The metabolic phenotype in obesity: fat mass, body fat distribution, and adipose tissue function. *Obes Facts*. 2017;10(3):207-215. doi:10.1159/000471488
28. Fritz K, Salavastru C, Gyurova M. Clinical evaluation of simultaneously applied monopolar radiofrequency and targeted pressure energy as a new method for noninvasive treatment of cellulite in postpubertal women. *J Cosmet Dermatol*. 2018;17(3):361-364. doi:10.1111/jocd.12525
29. Kinney BM, Kanakov D, Yonkova P. Histological examination of skin tissue in the porcine animal model after simultaneous and consecutive application of monopolar radiofrequency and targeted pressure energy. *J Cosmet Dermatol*. 2020;19(1):93-101. doi:10.1111/jocd.13235
30. Hantash BM, Ubeid AA, Chang H, Kafi R, Renton B. Bipolar fractional radiofrequency treatment induces neoelastogenesis and neocollagenesis. *Lasers Surg Med*. 2009;41(1):1-9. doi:10.1002/lsm.20731
31. Dayan E, Theodorou S, Rohrich RJ, Burns AJ. Aesthetic applications of radiofrequency: lymphatic and perfusion assessment. *Plast Reconstr Surg Glob Open*. 2020;8(10):e3193. doi:10.1097/GOX.0000000000003193
32. Nassar AH, Dorizas AS, Shafai A, Sadick NS. A randomized, controlled clinical study to investigate the safety and efficacy of acoustic wave therapy in body contouring. *Dermatol Surg*. 2015;41(3):366-370. doi:10.1097/DSS.0000000000000290
33. Bayrakci Tunay V, Akbayrak T, Bakar Y, Kayihan H, Ergun N. Effects of mechanical massage, manual lymphatic drainage and connective tissue manipulation techniques on fat mass in women with cellulite. *J Eur Acad Dermatol Venereol*. 2010;24(2):138-142. doi:10.1111/j.1468-3083.2009.03355.x
34. Duncan DI. Combination treatment for buttock and abdominal remodeling and skin improvement using HIFEM procedure and simultaneous delivery of radiofrequency and targeted pressure energy. *J Cosmet Dermatol*. Published online October 22, 2021. doi:10.1111/jocd.14554

How to cite this article: Duncan DI, Busso M. Effectiveness of combined use of targeted pressure energy, radiofrequency, and high-intensity focused electromagnetic fields to improve skin quality and appearance of fat and muscle tissue in different body parts. *J Cosmet Dermatol*. 2022;00:1-6. doi: 10.1111/jocd.15280