

# Noninvasive skin tightening: focus on new ultrasound techniques

Sabrina Guillen Fabi

Goldman, Butterwick, Fitzpatrick,  
Groff and Fabi, Cosmetic Laser  
Dermatology, San Diego, CA, USA

**Abstract:** Microfocused ultrasound (MFU) has been recently developed to meet the ever-growing public demand for achieving significant, noninvasive skin lifting and tightening. MFU can be focused on subcutaneous tissue where the temperature briefly reaches greater than 60°C, producing small (<1 mm<sup>3</sup>) thermal coagulation points to a depth of up to 5 mm within the mid-to-deep reticular layer of the dermis and subdermis. The intervening papillary dermal and epidermal layers of skin remain unaffected. The application of heat at these discrete thermal coagulation points causes collagen fibers in the facial planes such as the superficial musculoaponeurotic system and platysma, as well as the deep reticular dermis, to become denatured, contracting and stimulating de novo collagen. A commercially available device combines MFU with high-resolution ultrasound imaging (MFU-V), which enables visualization of tissue planes to a depth of 8 mm and allows the user to see where the MFU energy will be applied (Ultherapy®; Ulthera Inc., Mesa, AZ, USA). Using different transducers, MFU-V treatment can be customized to meet the unique physical characteristics of each patient by adjusting energy and focal depth of the emitted ultrasound. By targeting the facial superficial musculoaponeurotic system, noninvasive tightening and lifting of sagging facial and neck skin and improvements in the appearance of wrinkles can be achieved. MFU-V can also improve lines and wrinkles of the décolleté. Treatment protocols for the use of MFU-V continue to be refined, and its use in combination with other rejuvenation techniques has been demonstrated. Brief discomfort that often occurs during treatment can be minimized with oral nonsteroidal anti-inflammatory drugs. Other treatment-related adverse events include transient erythema, edema, and occasional bruising. MFU-V is best suited for patients with mild-to-moderate skin and soft tissue laxity. For older patients with severe skin laxity and marked platysmal banding, surgical treatment should be considered.

**Keywords:** microfocused ultrasound, skin tightening, skin lifting, facial rejuvenation, ultherapy

## Introduction

To meet the ever-growing public demand for achieving significant, noninvasive skin lifting and tightening, numerous devices employing a range of energy technologies have been recently developed including focused ultrasound. In many ways, focused ultrasound is similar to the ultrasound used in medical imaging; however, it is highly convergent and uses different frequencies of acoustic energy.<sup>1</sup> Special transducers direct the ultrasound energy to a small focal point where elevated temperatures are capable of causing tissue coagulation. Similar to medical imaging, the focused beam of ultrasound energy can be made to pass harmlessly through the skin, allowing the focal point to target subcutaneous tissues, such as the superficial musculoaponeurotic

Correspondence: Sabrina Guillen Fabi  
Goldman, Butterwick, Fitzpatrick,  
Groff and Fabi, Cosmetic Laser  
Dermatology, 9339 Genesee Avenue,  
Suite 300, San Diego, CA 92121, USA  
Tel +1 858 657 1003  
Fax +1 858 657 9294  
Email [sfabi@clderm.com](mailto:sfabi@clderm.com)

system (SMAS), where protein around the focal point will reach over 65°C and be denatured within milliseconds.<sup>2</sup>

A distinction must be made between the two primary types of focused ultrasound used in medicine.<sup>3</sup> As its name implies, high-intensity focused ultrasound (HIFU) uses high-energy ultrasound and is used primarily for medical applications, such as nonsurgically ablating tumors.<sup>4</sup> HIFU can also be used to ablate adipose tissue for body contouring. For example, HIFU used for ablating adipose tissue uses 47–59 J/cm<sup>2</sup> of energy, a frequency of about 2 MHz, and a focal depth<sup>5</sup> of 1.1–1.8 cm to ablate subcutaneous fat and achieve a reduction in body circumference.<sup>6,7</sup>

In contrast, microfocused ultrasound (MFU) uses much lower ultrasound energy to treat the superficial layers of the skin. MFU uses 0.4–1.2 J/mm<sup>2</sup> of energy, a frequency of 4–10 MHz, and a focal depth of only 1.5–4.5 mm.<sup>8</sup> Despite its lower energy, MFU is capable of heating tissue to greater than 60°C, producing small (<1 mm<sup>3</sup>) thermal coagulation points to a depth of up to 5 mm within the mid-to-deep reticular layer of the dermis and subdermis while sparing overlying papillary dermal and epidermal layers of skin.<sup>9</sup>

The action of HIFU involves thermal as well as cavitation to cause cell disruption and cell death. The injury that occurs when HIFU is applied to living tissue is the result of a thermo-mechanical process. As the name implies, this involves two distinct but inseparable mechanisms. The ultrasound energy which is absorbed by tissue causes molecular vibrations resulting in heat generation and a rapid rise in temperature at the focal zone. Additionally, the repeated compressions and rarefactions that occur as waves of ultrasound propagation through living tissue result in powerful shear forces. On a cellular level, this microscopic shearing motion results in frictional heating.<sup>10</sup> In living tissue, these repeated compressions and rarefactions cause microscopic bubbles that form in biological fluids to grow in size, and oscillate until they eventually implode. High temperatures can occur inside the bubbles, and the forces caused by collapsing bubbles can cause cell death through mechanical processes.<sup>2</sup>

MFU relies only on heat to achieve its effects on tissue. The goal is to elevate the local temperature to at least 65°C, the temperature at which collagen contraction begins to occur.<sup>11</sup> By targeting highly focused ultrasound energy in discrete areas within dermal and subdermal tissues, MFU causes discrete thermal coagulation points while sparing adjacent nontarget tissues.<sup>9,12,13</sup> In addition to local coagulation, the application of heat causes collagen fibers in the subcutaneous fat layer to become denatured and contract.<sup>14</sup> This occurs by breaking intramolecular hydrogen bonds causing the chains

of collagen to fold and assume a more stable configuration resulting in shorter, thicker collagen. In addition, de novo collagen formation occurs within the areas of thermal tissue coagulation and new viscoelastic collagen forms, resulting in the lifting and tightening of lax skin. The development of MFU enables targeting the facial SMAS, a fan-shaped structure that covers the face<sup>15</sup> and connects the facial muscles with the dermis.<sup>16</sup> The net result is noninvasive tightening and lifting of sagging facial and neck skin and improvements in the appearance of wrinkles.<sup>17</sup> Recently, MFU has also been applied to improve lines and wrinkles of the décolleté.

Treatment with MFU can be customized to meet the unique physical characteristics of each patient by adjusting energy and focal depth of the emitted ultrasound. These options differ in their geometric focus and wavelength configurations, whereby the depth and quantity of energy delivered during treatment can be varied for a desired effect within the target tissue layer. Currently available transducers emit frequencies of 10.0 MHz, 7.0 MHz, and 4.0 MHz with focal depths of 1.5 mm, 3.0 mm, and 4.5 mm, respectively. Two narrow 10 MHz/1.5 mm and 7.0 MHz/3.0 mm transducers are also available<sup>18</sup> to allow for energy deposition in smaller anatomical regions that are harder to reach with larger transducers. Together, these transducers can be used in combination to target the dermis (1.5 mm), deep dermis (3.0 mm), or the subdermal tissues (4.5 mm) including the SMAS layer.

A commercially available MFU device is also capable of high-resolution ultrasound imaging (MFU-V), which enables visualization of tissue planes to a depth of 8 mm and allows the user to see where the MFU energy will be applied (Ultherapy®; Ulthera Inc., Mesa, AZ, USA).<sup>18</sup> Each hand-piece uses high-resolution ultrasonography that is capable of clearly imaging the targeted facial anatomy, including skin, subcutaneous fat, and SMAS, facial musculature, and the underlying bone. This ensures treatment at the proper depth and allows avoidance of inadvertent treatment of nontarget tissue, such as bone and larger blood vessels. The imaging also allows the operator to ensure proper acoustic coupling between the transducer and skin before the application of MFU energy.

## Efficacy of MFUS

After preclinical studies demonstrated the ability of MFU to reach the SMAS<sup>9,19</sup> and cause tissue contraction,<sup>12</sup> a clinical trial assessed the ability of this MFU-V device to tighten the brow by treating the full face and neck.<sup>8</sup> Subjects were medicated with topical anesthetic, and MFU-V was applied

to the forehead, temples, cheeks, submental region, and side of neck using three transducers emitting 4 MHz and 7 MHz at a focal depth of 4.5 mm and 7 MHz at a focal depth of 3.0 mm. Among the evaluable subjects (N=35), 90 days after treatment, 30 (86%) were judged by blinded observers to show clinically significant brow-lift with a mean elevation in eyebrow height of 1.7 mm. In the author's personal experience, MFU-V is an ideal treatment in a number of anatomic regions, as different facial and nonfacial areas have a wide range of thicknesses, allowing one to target both cutaneous layers in the skin, such as the reticular dermis, and fibromuscular layers, such as the submuscular aponeurotic system on the face and superficial fibromuscular tissue-encasing muscles on the body.

Among patients treated on the neck in one study (N=70), quantitative assessment indicated that 72.9% of subjects achieved a visible tissue lift of  $\geq 20.0$  mm<sup>2</sup> of the submental area.<sup>20</sup> A blinded assessment of baseline and 3-month post-treatment photographs determined that 68.6% of subjects had improvement in the submental and neck areas, and an improvement in the appearance of their face and neck was perceived by 67% of treated subjects.

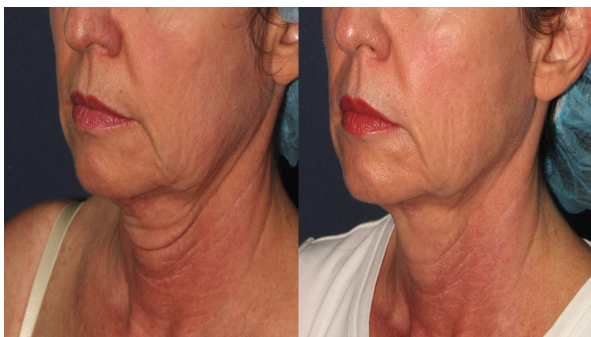The beneficial effects of MFU-V are also very durable. To evaluate the safety and efficacy of MFU-V for noninvasive treatment of facial and neck skin laxity, women treated with MFU-V on the face and upper neck were assessed in our practice.<sup>21</sup> Among patients evaluated at 180 days (N=45), physician Global Aesthetic Improvement Scale (GAIS) scores revealed that 77.7% patients achieved improvement, and subject GAIS scores showed that 77.8% of subjects perceived improvement (Figure 1). Based on blinded reviewer assessments, 67% of subjects showed improvement in appearance at 180 days.

The efficacy of MFU-V treatment is improved when multiple treatment passes are used.<sup>22</sup> In one study, areas of

the face and neck were treated with a 4 MHz and 4.5 mm transducer followed by a 7 MHz and 3.0 mm transducer. Among the evaluable patients (N=10), two blinded clinicians determined that eight showed clinical improvement 90 days after treatment, while nine subjects reported improvement. The beneficial effects of dual-depth treatment passes with MFU-V for tightening and lifting of cheek tissue, improving jawline definition, and reducing submental skin laxity were further demonstrated in a large prospective study.<sup>23</sup> Among evaluable subjects, at 90 days posttreatment (N=93), blinded reviewers reported improved skin laxity in 58.1%, and quantitative assessments revealed improved skin laxity in 63.6%. At day 90, 65.6% of patients perceived improvement in the skin laxity of the lower half of their face/neck.

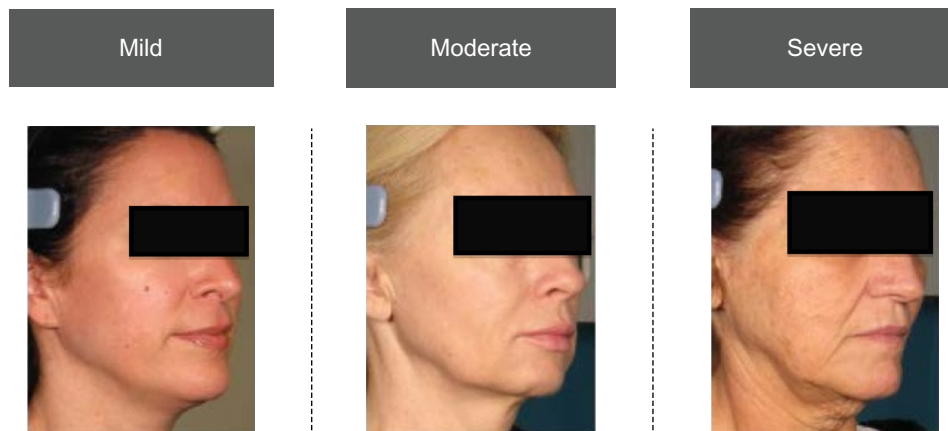
A further refinement is treating patients with MFU-V at two treatment depths and also varying vector direction of treatment lines and total applied energy. Using the same energy output, one study reported that 15 vertically oriented treatment lines in both 3.0 mm and 4.5 mm tissue depths produced significantly greater lifting than 15 horizontally placed treatment lines in the opposing brows and marionette lines.<sup>24</sup> Overall, sites receiving treatment lines and higher energy at dual depths produced significantly greater lifting. In the author's experience, dual-depth treatment is always performed. The number of total lines per treatment are customized to the patient depending on their baseline laxity (Figure 2), with patients showing mild laxity typically receiving 500–600 lines for a full face/upper neck treatment, patients with moderate laxity receiving between 600 and 700 lines, and those with severe laxity necessitating the manufacturer-recommended protocol that calls for approximately 800 lines. One vector per cheek is typically delivered, utilizing 15 vertically oriented treatment lines.

MFU-V has also been used off-label as an effective procedure for improving infraorbital skin laxity. Because the skin around the eye is relatively thin, a 7.0 MHz and 3.0 mm focal depth transducer was used in one report to deliver a single pass over the area to generate thermal coagulation points spaced approximately 3.0–5.0 mm apart<sup>25</sup> and assessed after 6 months. Based on objective assessments, 13/15 subjects (86.7%) were Improved or Much Improved, and based on subjective assessments, all 15 (100%) were Improved or Much Improved. In a similar study, MFU-V was used to correct lower eyelid laxity.<sup>26</sup> In that report, a 1.5 mm probe was used to tighten loose eyelid skin and the deep dermis, and a 3.0 mm probe was used to tighten the orbicularis oculi muscle and the orbital septum. Using computed tomography, the mean (standard deviation [SD]) change in the distance



**Figure 1** XX-year-old female; one MFU-V treatment to full face and full neck; total treatment lines are XXX; 8 months later.  
**Abbreviation:** MFU, microfocused ultrasound.

### Customizing treatment



**Figure 2** Customizing treatment depending on laxity severity.

from a line between the most inferior point of the supra-orbital rim and the most superior point of the infraorbital rim to the most protruding point of the orbital septum was 0.51 (0.23) for the right eye and 0.54 (0.17) for the left eye. It is important to always stay on bone when treating periorbitally as the ultrasound waves will bypass any protective eye shield and can cause corneal injury.

Aging skin is characterized by several independent changes including the breakdown of collagen, redistribution of subcutaneous fat, and resorption and posterior remodeling of maxillary bone. As no single treatment can correct these changes, a combination of techniques is required, such as intense-pulsed light (IPL), poly-L-lactic acid (PLLA), and MFU-V.<sup>27</sup> IPL treatments are performed first, followed by MFU-V and finally PLLA implantation. When IPL and MFU-V are performed on the same day, they are performed prior to PLLA injections to avoid possible blood contamination of the IPL crystal or using ultrasound transducers, which are for multi-patient use. In addition, we suggest that IPL should be performed prior to MFU-V because the mild-to-moderate erythema caused by MFU-V may cause greater IPL energy absorption and possibly a greater likelihood of adverse events.

The currently available MFU-V device was cleared by the US Food and Drug Administration in 2009. Since that time, the use of MFU-V in cosmetic medicine continues to grow. Numerous studies have reported on the safe and effective use for tightening and lifting lax skin in other anatomical regions. These include the neck,<sup>20</sup> upper arms,<sup>28</sup> thighs,<sup>28</sup> and knees.<sup>28,29</sup>

Recently, the safety and efficacy of MFU-V for treating décolletage laxity and rhytids were evaluated.<sup>30</sup> Using a

validated 5-point photonumeric scale,<sup>31</sup> subjects with moderate-to-severe rhytids (N=24) were treated with MFU-V. There was a significant improvement in rhytids over time, with 46% and 62% of subjects showing a 1- to 2-point improvement after 90 days and 180 days, respectively (for each,  $P < 0.0001$ ). Mean (SD) midclavicular-to-nipple distance decreased from 20.9 (1.57) cm to 19.8 (1.50) cm and 19.5 (1.59) cm, at days 90 and 180, respectively (for each,  $P < 0.0001$ ). At day 90, 100% were improved based on subject GAIS scores, and 96% were improved based on physician GAIS scores (for each,  $P < 0.0001$ ). The results were the same after 180 days. All subjects were Satisfied or Very Satisfied with the results they achieved. Following the results of a similarly designed pivotal study of 125 subjects,<sup>32</sup> the MFU-V device received Food and Drug Administration clearance to noninvasively treat the chest to improve lines and wrinkles of the décolleté in July 2014.

### Safety of MFUS

The most commonly reported adverse event associated with MFU-V is brief discomfort during the treatment session. In one study, mean procedural pain scores for the cheek, submental, and submandibular regions were 5.68, 6.09, and 6.53, respectively, based on a visual analog scale from 0 (no pain) to 10 (maximal pain).<sup>23</sup> Subjects in one study (N=36) reported pain scores of 3–4, except for five subjects (13.8%) reporting scores  $> 7$ , but all completed the treatment.<sup>8</sup> In one small study, the pain reported during MFU-V was not significantly different than pulsed dye laser or radiofrequency skin-tightening devices.<sup>33</sup> Suggestions for minimizing treatment-related discomfort include pretreatment with oral acetaminophen or an oral nonsteroidal anti-inflammatory

drug (NSAID) such as ibuprofen or ketorolac and applying treatment using the lowest feasible energy setting.<sup>34</sup> Attempts to decrease treatment discomfort with topical lidocaine<sup>35</sup> and narcotic analgesics<sup>36</sup> proved to be no more effective than NSAIDs when using the deeper transducers (3.0 mm and 4.5 mm); however, topical anesthetics can be effective when using the 1.5 mm transducer. In the author's practice, 10% of patients typically only receive topical application of 23% lidocaine/7% tetracaine 60 minutes prior to the procedure, and 15% also receive an oral diazepam (5–10 mg) 30 minutes before treatment, but the majority of patients receive a combination of topical anesthesia, oral diazepam (5–10 mg), and an intramuscular injection of 50–100 mg of meperidine and 50 mg of hydroxyzine 30 minutes prior to treatment.<sup>21</sup> Other reported MFU-V-related adverse events include transient erythema, edema, and occasional bruising.<sup>8,22,25,37</sup> Uncommon events include post-inflammatory hyperpigmentation 1 month posttreatment, muscle weakness,<sup>34</sup> transient numbness,<sup>24,38,39</sup> and striated linear skin patterns or wheals.<sup>8,23,24,34,38</sup> These wheals appear to be due to poor treatment technique and are more likely to be associated with the use of the 3 mm and 1.5 mm transducers.<sup>34</sup> Even when MFU-V is combined with other treatment modalities, the recent report by Friedmann et al confirmed the safety and enhanced efficacy of utilizing all three rejuvenation techniques, often in a single session.<sup>27</sup>

## Patient selection

There are relatively few absolute contraindications to the use of MFU-V. These include infections and open skin lesions at the target treatment area, active severe or cystic acne, and the presence of active metallic implants such as pacemakers or defibrillators in the treatment area. Precautions include treatment directly over keloids, implants, permanent dermal fillers, and the presence of factors that could alter or impair wound healing such as smoking.<sup>40,41</sup>

Although not everyone will achieve esthetic benefit from MFU-V, patient satisfaction will be increased by proper patient selection and setting realistic expectations. MFU-V is best suited for patients with mild-to-moderate skin and soft tissue laxity. An ideal patient is younger with normal wound healing because the clinical response to MFU-V treatment is partly dependent on de novo collagen synthesis and the so-called wound healing response.<sup>41</sup> Patients with greater age or worsening photodamaged skin, skin ptosis/laxity, and platysmal banding skin may require higher energy density during a single treatment or more than one treatment to achieve maximum benefit.<sup>40</sup> Older patients with extensive photoaging, severe skin laxity, marked platysmal banding, and a very

heavy neck are not good candidates for treatment with MFU-V and should be recommended for surgical treatment.<sup>34</sup>

There is no apparent association between clinical improvements and age, Fitzpatrick skin type, alcohol intake, or major illness.<sup>21</sup> In one study, outcomes were better in patients with BMI  $\leq 30$  kg/m<sup>2</sup>.<sup>23</sup> No change was detected in more than half of the patients whose BMI exceeded 30 kg/m<sup>2</sup>.

## Conclusion

MFU has been recently developed to meet the public demand for achieving significant, noninvasive skin lifting and tightening. The application of MFU in small discrete thermal coagulation points within the mid-to-deep reticular layer of the dermis and subdermis causes collagen fibers to contract and stimulates de novo collagenesis. Tightening and lifting of sagging facial and neck skin and improvements in the appearance of wrinkles can be achieved by targeting the facial SMAS and platysma. Combining MFU with high-resolution ultrasound imaging (MFU-V) allows the user to visualize where the MFU energy will be applied. By using transducers with different energy output and focal depth, MFU-V treatment can be customized to meet the unique physical characteristics of each patient. MFU-V is best suited for patients with mild-to-moderate skin and soft tissue laxity.

## Acknowledgment

The author acknowledges the editorial assistance of Dr Carl Hornfeldt during the preparation of this manuscript.

## Disclosure

The author is a consultant for Ulthera, Inc. The author reports no other conflict of interest in this work.

## References

1. Kim YS, Rhim H, Choi MJ, Lim HK, Choi D. High-intensity focused ultrasound therapy: an overview for radiologists. *Korean J Radiol.* 2008;9:291–302.
2. Dubinsky TJ, Cuevas C, Dighe MK, Kolokythas O, Hwang JH. High-intensity focused ultrasound: current potential and oncologic applications. *AJR Am J Roentgenol.* 2008;190:191–199.
3. Sklar LR, El Tal AK, Kerwin LY. Use of transcuteaneous ultrasound for lipolysis and skin tightening: a review. *Aesthetic Plast Surg.* 2014;38(2):429–441.
4. Orsi F, Arnone P, Chen W, Zhang L. High intensity focused ultrasound ablation: a new therapeutic option for solid tumors. *J Cancer Res Ther.* 2010;6:414–420.
5. Gadsden E, Aguilar MT, Smoller BR, Jewell ML. Evaluation of a novel high-intensity focused ultrasound device for ablating subcutaneous adipose tissue for noninvasive body contouring: safety studies in human volunteers. *Aesthet Surg J.* 2011;31(4):401–410.
6. Fatemi A, Kane MA. High-intensity focused ultrasound effectively reduces waist circumference by ablating adipose tissue from the abdomen and flanks: a retrospective case series. *Aesthetic Plast Surg.* 2010;34:577–582.

7. Robinson DM, Kaminer MS, Baumann L, et al. High-intensity focused ultrasound for the reduction of subcutaneous adipose tissue using multiple treatment techniques. *Dermatol Surg.* 2014;40(6):641–651.
8. Alam M, White LE, Martin N, Witherspoon J, Yoo S, West DP. Ultrasound tightening of facial and neck skin: a rater-blinded prospective cohort study. *J Am Acad Dermatol.* 2010;62:262–269.
9. Laubach HJ, Makin IR, Barthe PG, Slayton MH, Manstein D. Intense focused ultrasound: evaluation of a new treatment modality for precise microcoagulation within the skin. *Dermatol Surg.* 2008;34:727–734.
10. Duck FA. *Physical Properties of Tissue.* London: Academic Press; 1990.
11. Hayashi K, Thabit G 3rd, Massa KL, et al. The effect of thermal heating on the length and histological properties of the glenohumeral joint capsule. *Am J Sports Med.* 1997;25(1):107–112.
12. White WM, Makin IR, Barthe PG, Slayton MH, Gliklich RE. Selective creation of thermal injury zones in the superficial musculoaponeurotic system using intense ultrasound therapy: a new target for noninvasive facial rejuvenation. *Arch Facial Plast Surg.* 2007;9:22–29.
13. Gliklich RE, White WM, Slayton MH, Barthe PG, Makin IR. Clinical pilot study of intense ultrasound therapy to deep dermal facial skin and subcutaneous tissues. *Arch Facial Plast Surg.* 2007;9:88–95.
14. Ferraro GA, De Francesco F, Nicoletti G, Rossano F, D'Andrea F. Histologic effects of external ultrasound-assisted lipectomy on adipose tissue. *Aesthetic Plast Surg.* 2008;32:111–115.
15. Thaller SR, Kim S, Patterson H, Wildman M, Daniller A. The sub-muscular aponeurotic system (SMAS): a histologic and comparative anatomy evaluation. *Plast Reconstr Surg.* 1990;86:690–696.
16. Ghassemi A, Prescher A, Riediger D, Axer H. Anatomy of the SMAS revisited. *Aesthetic Plast Surg.* 2003;27:258–264.
17. Minkis K, Alam M. Ultrasound skin tightening. *Dermatol Clin.* 2014;32(1):71–77.
18. ULTHERA®. *Operation and Maintenance Manual.* Mesa, AZ: Ulthera Inc.
19. White WM, Makin IR, Slayton MH, Barthe PG, Gliklich R. Selective transcutaneous delivery of energy to porcine soft tissues using intense ultrasound (IUS). *Lasers Surg Med.* 2008;40(2):67–75.
20. Kenkel JM. Evaluation of the Ulthera System for achieving lift and tightening cheek tissue, improving jawline definition and submental skin laxity. Presented at: American Society for Laser Medicine and Surgery; 2013; Boston, MA.
21. Fabi SG, Goldman MP. Retrospective evaluation of micro-focused ultrasound for lifting and tightening the face and neck. *Dermatol Surg.* 2014;40(5):569–575.
22. Lee HS, Jang WS, Cha YJ, et al. Multiple pass ultrasound tightening of skin laxity of the lower face and neck. *Dermatol Surg.* 2012;38:20–27.
23. Oni G, Hoxworth R, Teotia S, Brown S, Kenkel JM. Evaluation of a microfocused ultrasound system for improving skin laxity and tightening in the lower face. *Aesthet Surg J.* 2014;34(7):1099–1110.
24. Sasaki GH, Tevez A. Clinical efficacy and safety of focused-image ultrasonography: a 2-year experience. *Aesthet Surg J.* 2012;32:601–612.
25. Suh DH, Oh YJ, Lee SJ, et al. A intense-focused ultrasound tightening for the treatment of infraorbital laxity. *J Cosmet Laser Ther.* 2012;14:290–295.
26. Pak CS, Lee YK, Jeong JH, Kim JH, Seo JD, Heo CY. Safety and efficacy of Ulthera in the rejuvenation of aging lower eyelids: a pivotal clinical trial. *Aesthetic Plast Surg.* 2014;38(5):861–868.
27. Friedmann DP, Fabi SG, Goldman MP. Combination of intense pulsed light, Sculptra, and Ultherapy for treatment of the aging face. *J Cosmet Dermatol.* 2014;13(2):109–118.
28. Alster TS, Tanzi EL. Noninvasive lifting of arm, thigh, and knee skin with transcutaneous intense focused ultrasound. *Dermatol Surg.* 2012;38:754–759.
29. Gold MH, Sensing W, Biron J. Use of micro-focused ultrasound with visualization to lift and tighten lax knee skin. *J Cosmet Laser Ther.* 2014;2:1–5.
30. Fabi SG, Massaki A, Eimpunth S, Pogoda J, Goldman MP. Evaluation of microfocused ultrasound with visualization for lifting, tightening, and wrinkle reduction of the décolletage. *J Am Acad Dermatol.* 2013;69:965–971.
31. Fabi S, Bolton J, Goldman MP, Guha I. The Fabi-Bolton chest wrinkle scale: a pilot validation study. *J Cosmet Dermatol.* 2012;11(3):229–234.
32. Dayan SH, Fabi SG, Goldman MP, Kilmer SL, Gold MH. Prospective, multi-center, pivotal trial evaluating the safety and effectiveness of micro-focused ultrasound with visualization (MFU-V) for improvement in lines and wrinkles of the décolletage. *Plast Reconstr Surg.* 2014;134(4 suppl 1):123–124.
33. Kakar R, Ibrahim O, Disphanurat W, et al. Pain in naïve and non-naïve subjects undergoing nonablative skin tightening dermatologic procedures: a nested randomized control trial. *Dermatol Surg.* 2014;40(4):398–404.
34. Brobst RW, Ferguson M, Perkins SW. Noninvasive treatment of the neck. *Facial Plast Surg Clin North Am.* 2014;22:191–202.
35. Gitt S. Double-blind, randomized, controlled split-face trial to assess the efficacy and safety of a liposomal lidocaine topical for pain management during microfocused ultrasound treatment. Presented at: The Aesthetic Meeting; 2012; Vancouver, BC.
36. Sunderam H. Propective double-blind, randomized pilot study comparing ibuprofen to a narcotic for pain management during micro-focused ultrasound treatment. Presented at: American Society for Dermatologic Surgery; 2011; Washington, DC.
37. Chan NP, Shek SY, Yu CS, Ho SG, Yeung CK, Chan HH. Safety study of transcutaneous focused ultrasound for non-invasive skin tightening in Asians. *Lasers Surg Med.* 2011;43:366–375.
38. Suh DH, Shin MK, Lee SJ, et al. Intense focused ultrasound tightening in Asian skin: clinical and pathologic results. *Dermatol Surg.* 2011;37:1595–1602.
39. Jeong KH, Suh DH, Shin MK, Lee SJ. Neurologic complication associated with intense focused ultrasound. *J Cosmet Laser Ther.* 2013;16:43–44.
40. Brobst RW, Ferguson M, Perkins SW. Ulthera: initial and six month results. *Facial Plast Surg Clin North Am.* 2012;20:163–176.
41. MacGregor JL, Tanzi EL. Microfocused ultrasound for skin tightening. *Semin Cutan Med Surg.* 2013;32:18–25.

## Clinical, Cosmetic and Investigational Dermatology

### Publish your work in this journal

Clinical, Cosmetic and Investigational Dermatology is an international, peer-reviewed, open access, online journal that focuses on the latest clinical and experimental research in all aspects of skin disease and cosmetic interventions. All areas of dermatology will be covered; contributions will be welcomed from all clinicians and

basic science researchers globally. This journal is indexed on CAS. The manuscript management system is completely online and includes a very quick and fair peer-review system, which is all easy to use. Visit <http://www.dovepress.com/testimonials.php> to read real quotes from published authors.

Submit your manuscript here: <http://www.dovepress.com/clinical-cosmetic-and-investigational-dermatology-journal>

Dovepress